

Ductal Carcinoma *In situ* and the Emergence of Diversity during Breast Cancer Evolution

D. Craig Allred,¹ Yun Wu,² Sufeng Mao,² Iris D. Nagtegaal,³ Sangjun Lee,¹ Charles M. Perou,⁴ Syed K. Mohsin,⁵ Peter O'Connell,⁶ Anna Tsimelzon,² and Dan Medina³

Abstract Purpose: Human invasive breast cancers (IBC) show enormous histologic and biological diversity. This study comprehensively evaluated diversity in ductal carcinoma *in situ* (DCIS), the immediate precursors of IBCs.

Experimental Design: The extent of diversity for conventional histologic grade and standard prognostic biomarkers assessed by immunohistochemistry was evaluated in a series of pure DCIS ($n = 200$) compared with a contemporaneous series of IBCs ($n = 200$). A subset of the DCIS ($n = 25$) was evaluated by DNA microarrays for the presence of luminal, basal, and erbB2 intrinsic subtypes. The extent of diversity within individual cases of DCIS ($n = 120$) was determined by assessing multiple regions independently for histologic (nuclear) grade and several biomarkers by immunohistochemistry, which approximate microarrays in determining intrinsic subtypes.

Results: DCIS showed a broad distribution of conventional histologic grades and standard biomarkers ranging from well to poorly differentiated, nearly identical to IBCs. Microarrays showed the same intrinsic subtypes in DCIS as in IBCs. However, higher resolution analysis showed that multiple histologic grades, biomarker phenotypes, and intrinsic subtypes often coexist within the same DCIS, and these diverse regions probably compete for dominance. Diversity within cases of DCIS was highly correlated with mutated p53 ($P = 0.0007$).

Conclusions: These results support the hypothesis that poorly differentiated DCIS gradually evolve from well-differentiated DCIS by randomly acquiring genetic defects resulting in increasingly abnormal cellular features. This diversity is amplified by defects resulting in genetic instability (e.g., p53 mutation), and the alterations are propagated to IBC in a manner independent of progression to invasion.

There are many models of human breast cancer evolution. One of the most well-established models, published by Wellings and Jensen over 30 years ago, proposed that the cellular origin of most breast cancers occurs in the normal terminal duct lobular unit (TDLU) and that there is an apparently continuous but nonobligatory progression from TDLUs to cancer through a series of increasingly abnormal stages over long

periods of time (1, 2), probably decades in most cases. The key stages in this progression are called hyperplastic enlarged lobular units (HELU), atypical ductal hyperplasia (ADH), ductal carcinoma *in situ* (DCIS), and invasive breast cancer (IBC) in today's terminology (3, 4). This model was originally based almost entirely on the evidence of gradual histologic continuity, but it has remained consistent with more recent discoveries, such as the escalating risk of developing IBC associated with the putative precursor lesions (3, 5–7), the shared genetic alterations between the precursors and IBC, especially when they occur in the same breasts (8–10), and histologic and genetic similarities with genetically engineered mouse models (11–13).

HELUs and ADH, at the near end of this evolutionary spectrum, show very well-differentiated histologic and biological features (14), although the latter features have not been studied in great detail. IBCs, at the far end of the spectrum, show enormous histologic and biological diversity, ranging from very well to very poorly differentiated, based on many comprehensive studies. DCIS reside between these extremes and are usually divided into two (e.g., noncomedo versus comedo) or three (e.g., low versus intermediate versus high grade) categories reflecting variations in the degree of differentiation (15–18). Thus, diversity of substantial degree seems to emerge at the stage of DCIS during breast cancer evolution, although detailed studies of DCIS are also relatively few and

Authors' Affiliations: ¹Department of Pathology, Washington University School of Medicine, St. Louis, Missouri; ²Breast Center and ³Department of Molecular and Cellular Biology, Baylor College of Medicine, Houston, Texas; ⁴Departments of Genetics and Pathology and Laboratory Medicine, Lineberger Comprehensive Cancer Center, University of North Carolina, Chapel Hill, North Carolina; ⁵Department of Pathology, Riverside Methodist Hospital, Columbus, Ohio; and ⁶Department of Human Genetics, VCU, Richmond, Virginia
Received 5/8/07; revised 8/16/07; accepted 9/17/07.

Grant support: Breast Cancer Research Foundation and NIH grant P50CA58183. The costs of publication of this article were defrayed in part by the payment of page charges. This article must therefore be hereby marked *advertisement* in accordance with 18 U.S.C. Section 1734 solely to indicate this fact.

Note: Supplementary data for this article are available at Clinical Cancer Research Online (<http://clincancerres.aacrjournals.org/>).

Requests for reprints: D. Craig Allred, Department of Pathology and Immunology, Washington University School of Medicine, 660 S. Euclid Avenue, Box 8118, St. Louis, MO 63110. Phone: 314-362-6313; Fax: 314-454-5001; Email: dcallred@path.wustl.edu.

©2008 American Association for Cancer Research.
doi:10.1158/1078-0432.CCR-07-1127

there are still many inconsistencies and unknowns. For example, ADH is widely regarded as the nonobligate precursor of noncomedo/low-grade DCIS, because they show similar well-differentiated features, but not of comedo/high-grade DCIS, because of their dissimilar poorly differentiated features, leading to speculation that the latter pursue a different course of evolution from occult precursors and the evolution of intermediate-grade lesions are essentially ignored.

These issues are important clinically because biological diversity in DCIS may influence the rate of progression to IBC, diversity propagated from DCIS to IBC may influence prognosis and sensitivity to specific therapies, and breast cancer prevention strategies should be based on an accurate understanding of how breast cancers evolve to be truly effective. The purpose of this study was to comprehensively characterize the histologic and biological diversity of DCIS compared with IBC to help further our understanding of DCIS and its role in breast cancer evolution.

Materials and Methods

Human tissue samples. Studies involving conventional histologic scoring and grading used available H&E-stained slides prepared from routine formalin-fixed paraffin-embedded tissue samples of consecutive cases of pure DCIS ($n = 200$), IBCs ($n = 200$), and the DCIS component of the IBCs ($n = 200$) from adult female patients at University of Texas Health Science Center San Antonio hospitals between 1980 and 1995 (average, 2.4 slides per case). The same cases were evaluated by immunohistochemistry on slides prepared from available formalin-fixed paraffin-embedded tissue blocks (1 block per case) for protein expression of standard prognostic biomarkers.

Studies involving DNA microarray analysis used 25 consecutive fresh-frozen samples of pure DCIS harvested from female breast surgeries at University of Texas Health Science Center San Antonio hospitals between 1990 and 1995 (these cases were a subset of those described above). The samples were manually dissected to obtain areas in which tumor cells comprised >75% of total cells using H&E-stained frozen sections for guidance.

Studies assessing histologic nuclear grade used available routine H&E-stained slides of consecutive clinical cases of pure DCIS ($n = 120$) at Baylor College of Medicine hospitals between 1996 and 2002 (average, 3.4 slides per case). A subset ($n = 112$) of these cases with available formalin-fixed paraffin-embedded tissue blocks were used in experiments assessing intrinsic subtypes by immunohistochemistry (average, 1.3 blocks per case).

The tissue harvesting and scientific studies had separate Baylor College of Medicine Institutional Review Board approval (protocols H-10493 and H-12585, respectively).

Conventional histologic scoring and grading. The Elston-Ellis modified Scarff-Bloom-Richardson method was used for conventional histologic scoring and grading of IBCs (19, 20). Briefly, scores from 1 to 3 were assigned to each of three histologic features, and the total histologic score (H-score) was used to determine overall grade. The features and general scoring criteria included (a) the degree (area) of tubule/gland formation in the tumor (1, >75%; 2, 10-75%; 3, <10%), (b) the degree of nuclear atypia or pleomorphism in the worst 10% of the tumor cells (1, mild; 2, moderate; 3, severe), and (c) the average mitotic count per high power field (HPF) based on counting a minimum of 10 HPFs (1, <1/HPF; 2, 1-2/HPF; 3, >2/HPF). Thus, for IBCs, H-scores ranged from 3 (the best differentiated) to 9 (the worst), and scores of 3 to 5 defined grade 1, 6 to 7 for grade 2, and 8 to 9 for grade 3.

The Elston-Ellis modified Scarff-Bloom-Richardson method was further modified for evaluating DCIS in this study by also scoring the extent (area) of central necrosis (1, <10%; 2, 10-50%; 3, >50%) because

this histologic feature (i.e., "comedo" necrosis) has played such a prominent role in the historical classification of DCIS. Thus, H-scores for DCIS ranged from 4 (the best differentiated) to 12 (the worst), and H-scores of 4 to 7 defined grade 1, 8 to 9 for grade 2, and 10 to 12 for grade 3.

Histologic nuclear grading. Black's nuclear grading method as modified by Fisher (21) was used to assess diversity of histologic differentiation within individual cases of pure DCIS. All available H&E-stained slides for each case were evaluated and scored for the presence and estimated percentage of tumor cells showing grade 1 (mild), grade 2 (moderate), or grade 3 (severe) nuclear atypia involving at least 5% of total tumor cells. This strategy was chosen over the modified Elston-Ellis modified Scarff-Bloom-Richardson method used for conventional histologic grading described above because of the superior accuracy and ease of scoring nuclear grade compared with other features in regions comprising a relatively small percentage of a tumor (e.g., it is difficult to score mitotic count if the area was smaller than 10 HPFs, etc.).

Assessment of biomarkers by immunohistochemistry. Each of the 200 consecutive cases of pure DCIS, IBCs, and the DCIS component of the IBCs evaluated for conventional histologic score and grade were also evaluated by immunohistochemistry for standard prognostic biomarkers, including estrogen receptor (ER), progesterone receptor (PR), erbB2, p53, and proliferation rate (Ki67). The immunohistochemistry used routine clinically validated methodology as previously described (4, 22-26). All biomarkers except Ki67 were quantified by the so-called Allred score (range, 0-8; refs. 24, 27) and "positive" was defined as scores ≥ 3 . Ki67 was quantified by absolute counting (>500 cells per case) and reported as average percentage of positive.

Each of the 112 consecutive cases of pure DCIS evaluated for diversity of histologic nuclear grade within individual tumors were also evaluated by immunohistochemistry for a set of biomarkers previously shown to be a reasonably accurate (80-90%) surrogate strategy for identifying intrinsic subtypes as originally defined by microarray studies of IBCs at the RNA level (28-30), including ER, GATA-binding protein 3 (GATA3), erbB2, cytokeratin 5/6 (CK5/6), CK18, and p53. The immunohistochemistry used routine methodology as previously described (23, 24, 28-30) and was quantified by the Allred score. For the purposes of this study, positive was defined as Allred scores ≥ 2 (any positive cells) and negative as Allred score of 0 (entirely negative). Diversity was defined as a change from positive to negative, or the opposite, for one or more biomarkers within an individual tumor, comparing regions with different histologic nuclear grades.

Microarray analysis. Total RNA for the microarray experiments was purified from the samples using the microRNA isolation kit (Stratagene), which is based on an aqueous/organic phase separation in guanidine isothiocyanate-phenol/chloroform extraction buffer. The isolated RNAs were then purified using RNeasy cleanup kit (Qiagen). The purified total RNA was then linearly amplified two rounds and converted to cDNA using Eberwine's RNA amplification method, which is based on an oligo-dT primer and T7 RNA polymerase (31, 32). The cDNA was then *in vitro* transcribed to biotin-labeled cRNA with the BioArray high-yield RNA transcript labeling kit (Enzo).

Gene expression was measured using U95Av2 human GeneChip oligo-based microarrays (Affymetrix). These earlier-generation microarrays contain transcripts for an estimated 63,000 probe sets interrogating ~54,000 UniGene clusters (many clusters are represented by multiple probe sets), corresponding to ~10,000 full-length annotated genes. Briefly, amplified biotinylated cRNA was further purified with the RNeasy mini kit (Qiagen) and fragmented (20 μ g cRNA) in 5 \times fragmentation buffer (200 mmol/L Tris-acetate + 500 mmol/L KOAc + 150 mmol/L MgOAc at pH 8.1) at a 4:1 volume ratio (cRNA/buffer) for 10 min to a range of 35 to 200 bases to optimize hybridization. Fragmented cRNA (20 μ g) was then mixed with hybridization controls (bioB, bioC, bioD, and cre) and hybridized to the microarrays for 16 h. After hybridization, the microarrays were washed, stained, and scanned to generate quantitative digital files.

Data analyses. dChip software⁷ was used to evaluate results from DNA microarray experiments. Normalization of raw data was by the invariant set normalization method, and expression was estimated by the perfect-match-only model. Analyses relevant to this study were restricted to an unsupervised hierarchical clustering using a list of 392 intrinsic genes (Supplementary Table S1) expressed in the samples. The intrinsic genes were distilled by one author (C.M.P.) from the results of previous microarray studies of IBC to optimally identify luminal, erbB2, and basal subtypes based on shared patterns of gene expression (33–35).

The results of experiments assessing protein expression by immunohistochemistry for the biomarkers ER, GATA3, erbB2, CK5/6, and CK18 were also subjected to unsupervised hierarchical clustering using dChip software for the purpose of identifying luminal, basal, and intrinsic subtypes (28–30).

Studies assessing diversity within individual cases of DCIS identified three categories: (a) cases showing no diversity, (b) cases showing diversity of histologic nuclear grade, and (c) cases showing diversity of both histologic nuclear grade and one or more biomarkers. The Student's *t* test was used to determine the significance of differences in the extent of diversity between these categories and the status of individual biomarkers.

Results

Histologic and biological diversity between cases of DCIS. The purpose of these experiments was to characterize and compare the range and distribution of histologic differentiation (H-scores) and standard prognostic biomarkers (ER, PGR, erbB2, p53, and Ki67) assessed by conventional methodologies in consecutive contemporaneous cases of pure DCIS, IBCs, and the DCIS component of the IBCs ($n = 200$ each; Fig. 1). Among the pure DCIS, there was a broad and relatively even distribution of H-scores ranging from 4 (the best differentiated) to 12 (the worst). Nearly all (>95%) cases with low H-scores (4–7) expressed high levels of ER and PGR in nearly all cells. The proportion of positive cases gradually declined thereafter to ~20% in cases with the highest H-scores, as well as the average proportion and intensity of positive cells in the cases (not shown). In contrast, alterations of erbB2 and p53 were uncommon (<10%) in DCIS with low H-scores, but gradually increased to ~60% in cases with the highest H-scores. Average proliferation rates (Ki67) also gradually increased from <5% to ~35% in direct correlation with H-scores. The distribution of H-scores and biomarkers were nearly identical in the IBCs and their DCIS component.

Intrinsic subtypes in DCIS. Twenty-five consecutive cases of pure DCIS were evaluated for gene expression at the RNA level by DNA microarray analysis, and the results were analyzed by unsupervised hierarchical clustering using dChip software and a list of 392 genes that define intrinsic subtypes in IBCs (Fig. 2). Luminal, basal, and erbB2 intrinsic subtypes were observed in DCIS at frequencies similar to previous studies of IBCs (44%, 8%, and 28%, respectively; ref. 35). A substantial (20%) proportion of DCIS did not conform to any of these subtypes (called "other/mixed" in this study), which has also been observed in up to 35% of IBCs (35). Average histologic scores/grades were much lower in luminal (5.4/1.1) and other/mixed (6.4/1.4) than erbB2 (10.0/2.4) and basal (10.0/2.5) DCIS, which has also been reported in IBCs (28–30).

Histologic and biological diversity within cases of DCIS. Conventional methods of histologic grading, such as the Elston-

Ellis modified Scarff-Bloom-Richardson method, used in studies summarized in Fig. 1 assign scores to the individual features of the grading system by following rules that have considerable leeway, and they are unable to convey the presence of internal variation. For example, the score for nuclear pleomorphism is assigned based on the area with the highest score comprising at least 10% of the tumor cells, so tumors with 15% and 100% of cells showing highly atypical nuclei would both get a score of 3 for this feature although they are very different. Similar examples can be made for the other grading features. In fact, the Elston-Ellis modified Scarff-Bloom-Richardson strategy is tacit acknowledgement of histologic diversity within breast cancers and a practical compromise to manage it in a routine clinical setting. The purpose of these experiments was to more precisely quantify the presence of histologic diversity (nuclear grade) within individual cases of DCIS and to compare certain biological characteristics of the cells associated with each grade within each case.

H&E-stained slides from 120 recent consecutive cases of pure DCIS were evaluated for the presence of cells showing different nuclear grades comprising at least 5% of total tumor cells (Fig. 3; Supplementary Fig. S1). No diversity of nuclear grade was identified in 54.2% of the cases, including 29.2%, 22.5%, and 2.5% composed entirely of nuclear grades 1, 2, and 3, respectively. The remaining 45.8% of cases showed areas of diversity, including 30.0% with grades 1 and 2, 6.6% with grades 2 and 3, and 9.2% with grades 1, 2, and 3.

A subset of the same cases with available paraffin blocks ($n = 112$) were further evaluated by immunohistochemistry for protein expression of several biomarkers (ER, GATA3, erbB2, CK5/6, CK18, and p53) associated with each nuclear grade within each case (Fig. 4; Table 1). No diversity of grade or biomarkers was observed in 51.8% of cases. Histologic diversity (>1 nuclear grade per case) was identified in the remaining 48.2% of cases. About one third of cases showing histologic diversity also showed biological diversity for one or more biomarkers, accounting for 13.4% of all cases. Diversity was observed with all the biomarkers, ranging from a high of 7.1% of cases for erbB2 and CK5/6 to a low of 0.9% of cases for CK18. The presence and extent of histologic and biological diversity was significantly ($P = 0.007$) associated with positive p53 status but not with the status of the other biomarkers (shown for ER and erbB2).

As expected, an unsupervised hierarchical clustering of the immunohistochemistry results segregated the DCIS into groups consistent with luminal A, luminal B, basal, and erbB2 intrinsic subtypes (Fig. 5). In this analysis, regions showing different nuclear grades and their associated biomarker phenotypes within individual tumors were treated as separate tumors. A large majority (73%) of cases with diversity of nuclear grade and biomarkers also showed diversity of intrinsic subtypes (>1 subtype per case) of nearly all possible combinations. It is important to keep in mind, however, that intrinsic subtypes defined by immunohistochemistry for a handful of biomarkers is only an approximation of intrinsic subtypes defined by comprehensive microarray analysis, and thus, the results in Fig. 4 may have turned out somewhat differently if the tumors had been evaluated by microarrays. Nonetheless, the immunohistochemistry results unequivocally show surprising diversity of substantial magnitude within individual tumors.

⁷ <http://www.dchip.org>

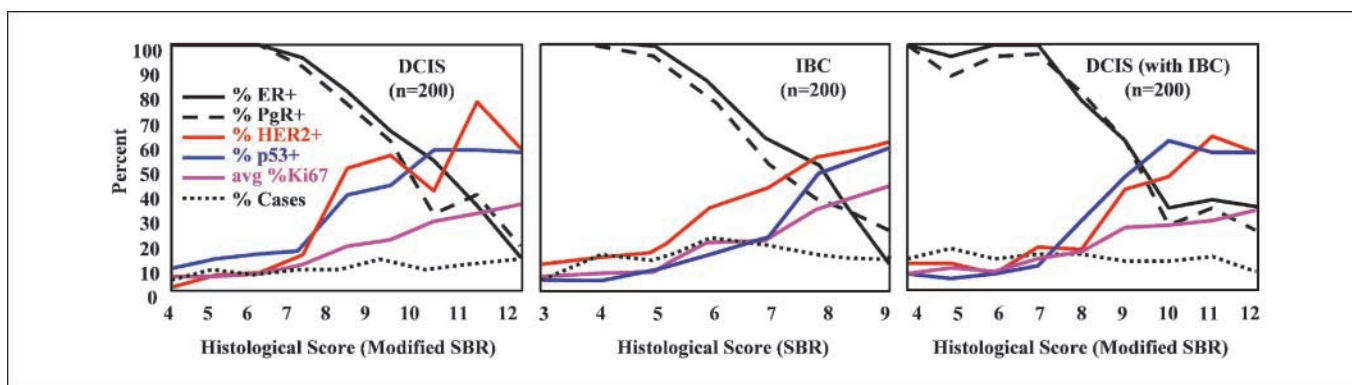


Fig. 1. Conventional histologic scores (H-scores) and standard prognostic biomarkers in pure DCIS, IBCs, and the DCIS component of the IBCs. Pure DCIS showed a broad and relatively even distribution of histologic scores ranging from 4 (the best differentiated) to 12 (the most poorly differentiated). Virtually, all cases with low H-scores (4-7) were strongly positive for ER and progesterone receptor. Receptor-positive cases gradually declined thereafter to a relatively small proportion (~20%) in cases with the highest H-scores. In contrast, HER2-positive and p53-positive cases (gene amplification/protein overexpression and mutation, respectively) were uncommon in cases with low H-scores (<10%) but gradually increased to a high proportion (~60%). Average proliferation rate also gradually increased from very low (<5%) to relatively high (~35%). The distributions of H-scores and biomarkers in a series of consecutive contemporaneous IBCs, as well as the DCIS component of the IBCs, were nearly identical to pure DCIS, suggesting that the diversity for these features evolves first in DCIS and is later propagated to IBC.

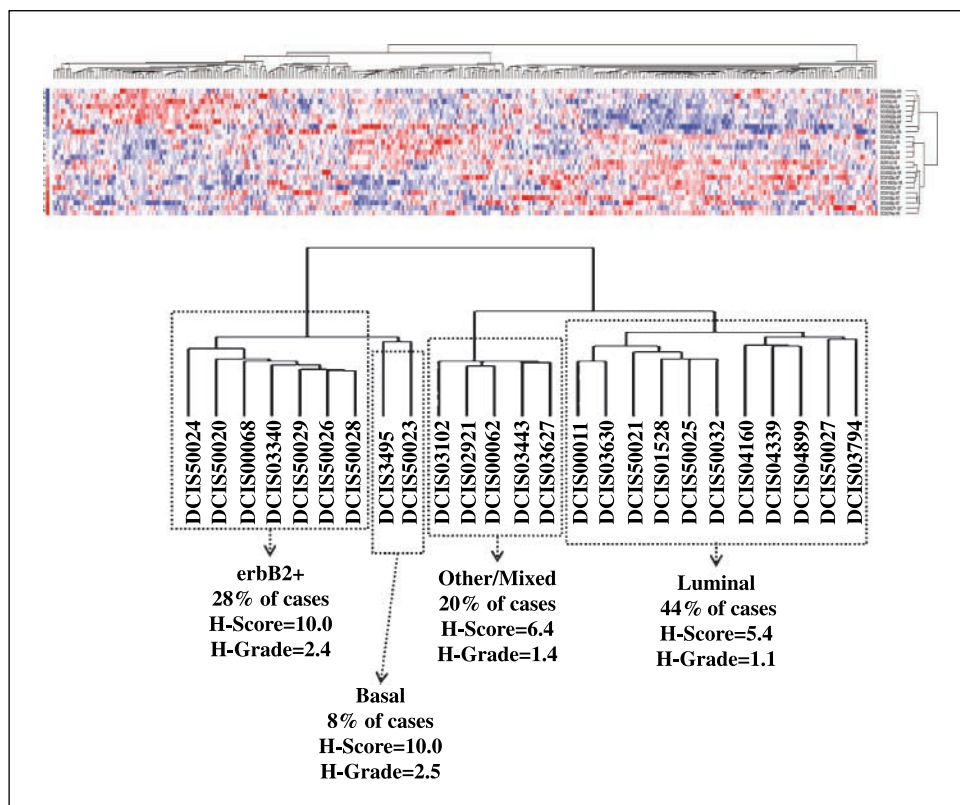
Discussion

The Wellings and Jensen model proposes an apparent nonobligatory continuum of progression from TDLUs to IBCs through a series of increasingly abnormal stages over long periods of time (1-3). Although it is artificial to define stages in a continuum such as this, there are important general characteristics distinguishing one from another that accumulate and increase with progression. For example, the transition from TDLUs to HELUs is characterized by increased growth due to epithelial hyperplasia. Alterations of cell adhesion and polarity

distinguish ADH from HELUs as the hyperplastic epithelium begins to pile up and distend acini. DCIS are characterized by further expansion of tumor volume, intraductal spread into other areas of the breast, and, most importantly, the appearance of increased histologic and biological diversity compared with earlier precursors. Invasion into surrounding stroma defines the transition of DCIS to IBC.

Although this model has been very useful, it oversimplifies a complex process, and there are still important inconsistencies and unknowns. For example, ADH as currently defined are uniformly composed of cells with very well-differentiated

Fig. 2. Pure DCIS evaluated by DNA microarrays. Twenty-five consecutive cases of pure DCIS were evaluated for gene expression at the RNA level by DNA microarrays, and the results were analyzed by unsupervised hierarchical clustering using dChip software and a list of 392 genes distilled from previous studies of IBCs to optimally identify so-called luminal, erbB2, basal intrinsic subtypes. These subtypes were also observed in DCIS at similar frequencies as in IBCs (44%, 28%, and 8%, respectively). A substantial (20%) proportion of DCIS did not conform to any of these subtypes (called other/mixed in this study), which has also been observed in IBCs. Average histologic scores/grades were much lower in luminal (5.4/1.1) and other/mixed (6.4/1.4) than erbB2 (10.0/2.4) and basal (10.0/2.5) DCIS.



histologic and biological features. DCIS are more diverse than ADH and are usually divided into two (e.g., comedo versus noncomedo) or three (e.g., low versus intermediate versus high grade) categories reflecting variations in the degree of differentiation (15–18). ADH is widely accepted as the nonobligate precursor of low-grade/noncomedo DCIS because they show similar well-differentiated features, but not of high-grade/comedo DCIS because of their poorly differentiated features, leading to speculation that the latter pursue a different course of evolution from occult precursors.

The results of this study show that DCIS vary on a broad continuum of differentiation, similar to IBCs and, along with other often overlooked evidence, support the hypothesis that most higher-grade DCIS gradually evolve from lower-grade DCIS and, thus, indirectly from ADH, by the random accumulation of genetic defects, which are propagated to IBC in a manner that is largely independent of progression to invasion (Fig. 6). This hypothesis is entirely compatible with current theories about breast cancer stem or progenitor cells, as discussed in more detail below.

Epidemiologic evidence supporting this hypothesis comes from studies showing that ADH is a risk factor for developing all histologic grades and subtypes of IBCs and, thus, the biological characteristics associated with these histologic features (36). Nearly all IBCs contain a noninvasive component (Supplementary Table S2) and the histologic and biological features of cells in both components are nearly identical (Fig. 1; ref. 37). If, as we believe, DCIS are the precursor of nearly all "ductal" IBCs (which account for 85-90% of all IBCs), then ADH is probably also a risk factor for the development of DCIS independent of its histologic and biological characteristics, although we are not aware of any studies specifically addressing this issue, most likely because there are no databases to address the question.

Other supporting evidence comes from this (Fig. 1) and earlier studies (15, 38–40) demonstrating that DCIS show a

broad range of differentiation in terms of conventional histologic scores/grades and standard prognostic biomarkers nearly identical to IBCs, suggesting that diversity for these features evolves first in DCIS and is later propagated to IBC, which was proposed by Gupta and colleagues nearly a decade ago (37). Although these features do not seem to influence the ability of DCIS to progress to invasive disease, they are associated with the rate of progression, as shown by studies showing a much higher rate of short-term local recurrence in higher-grade DCIS compared with lower-grade lesions treated by lumpectomy, although the rates converge with longer follow-up (41). DCIS and IBCs have also been shown to be very similar at the high resolution of global gene expression assessed by microarrays and other types of high throughput technologies (42–44).

The enormous range of histologic and biological diversity in DCIS (and IBCs for that matter) makes it nearly impossible to categorize them into two or three subtypes in any fundamentally meaningful way because cases exist with nearly every combination of features imaginable. This diversity also argues against the notion that ADH is a precursor of low-grade, but not high-grade, DCIS in the sense that it fails to explain the cellular origin of the majority of DCIS and because low-grade and high-grade DCIS do not really exist as distinct categories. Gradual change from well-differentiated to poorly differentiated DCIS seems more likely for the majority of cases, although some cases may bypass sequential change and evolve in a more direct or entirely different manner.

If it is true that higher-grade DCIS evolve from lower-grade DCIS, then there must be diversity within individual lesions at some point in time. A previous study by Lenington and colleagues noted the presence of multiple histologic growth patterns (e.g., cribriform, micropapillary, solid, etc.) in 46% of 100 DCIS evaluated (45). This study (Fig. 3) showed the presence of multiple histologic nuclear grades in 46% of 120 DCIS evaluated. Furthermore, nearly a third of the cases in our study showing diversity of nuclear grade also showed

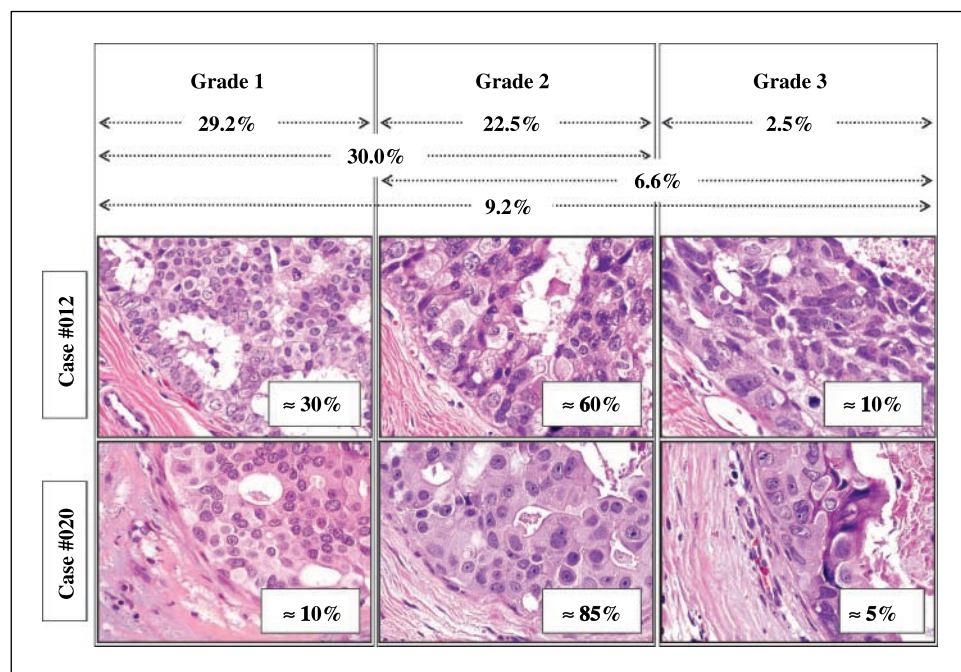


Fig. 3. Diversity of histologic nuclear grade within cases of pure DCIS. Recent consecutive cases of pure DCIS ($n = 120$) were evaluated for the presence of cells showing different histologic nuclear grades comprising at least 5% of total tumor cells. No diversity was identified in 54.2% of the cases, including 29.2%, 22.5%, and 2.5% composed entirely of nuclear grades 1, 2, and 3, respectively. The remaining 45.8% of cases showed areas of diversity, including 30.0% with grades 1 and 2, 6.6% with grades 2 and 3, and 9.2% with grades 1, 2, and 3.

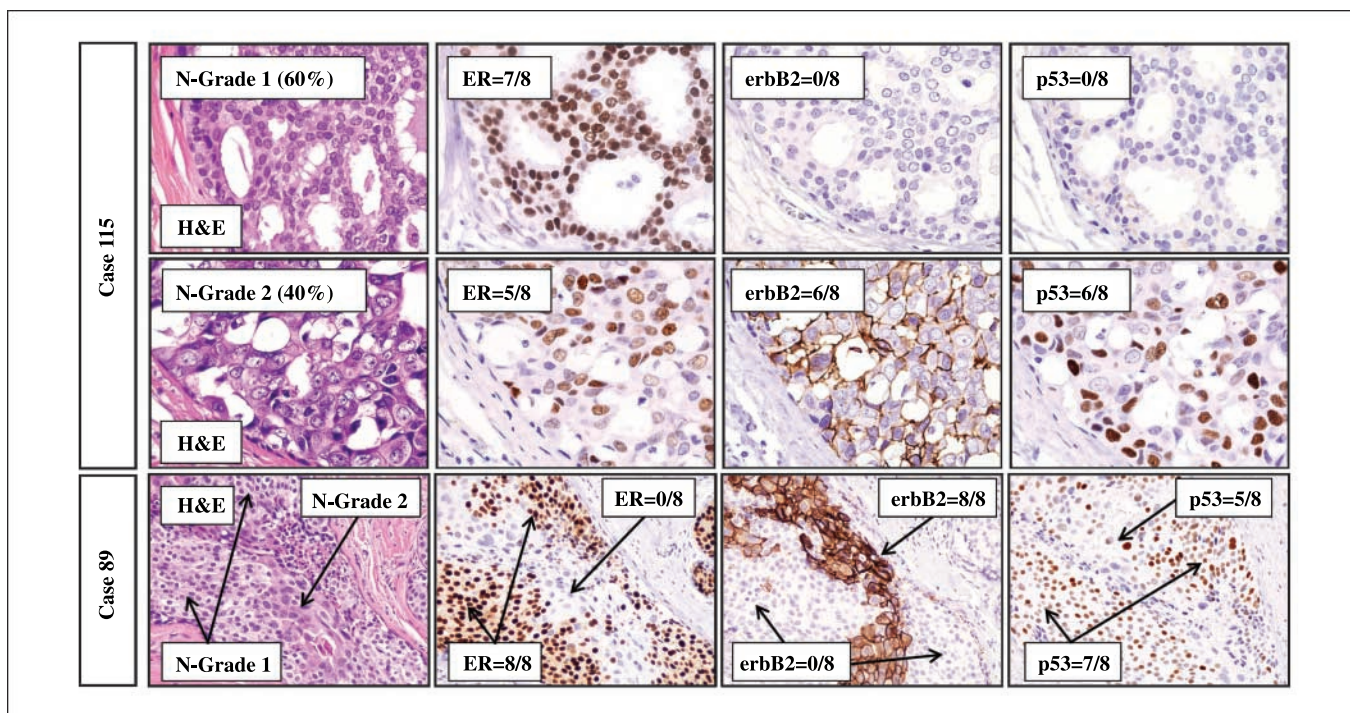


Fig. 4. The photomicrographs show examples of intra-tumor diversity in two cases. In case 115, ~60% of the tumor cells showed nuclear grade 1 histology, expressed very high levels of ER, and were negative (i.e., normal) for erbB2 and p53. The remaining 40% of the tumor cells showed nuclear grade 2 histology, expressed lower levels of ER (not counted as diversity), and were positive (amplified/overexpressed and mutated) for erbB2 and p53; erbB2 showed diversity at the protein and gene amplification levels in all four cases evaluated for both features. In case 89, the focus of DCIS shows cells with nuclear grade 1 histology at the periphery of the duct and nuclear grade 2 in the center. These areas of histologic diversity showed reciprocal phenotypes for ER and erbB2, whereas both regions were positive for p53.

diversity for several important biomarkers when comparing areas of different nuclear grade within individual tumors (Table 1 and Fig. 4). The presence and magnitude of any type of diversity was highly correlated ($P = 0.007$) with positive immunohistochemistry staining for p53, which is a surrogate for mutation of the gene (22, 46) but not with the other biomarkers evaluated. Mutation of p53 leads to genetic instability (47), suggesting that randomly acquired defects with this outcome (and there are many possibilities) may enable and/or accelerate the development of diversity in DCIS. This argument may be somewhat semantic in the sense that acquiring genetic instability in the first place may be fundamentally responsible for the characteristics pathologists use to define DCIS. Earlier precursors, such as HELUs and ADH, show far less genetic diversity than DCIS (at least in terms of magnitude if not specific defects; refs. 3, 9, 48), and it is feasible that alterations of development and/or differentiation, perhaps

adaptive in nature, are more important than heritable defects in the evolution of these lesions.

Our immunohistochemistry studies also showed the presence of multiple intrinsic subtypes within individual cases of DCIS (Fig. 5). Intratumor diversity of intrinsic subtypes has not been observed in microarray studies to date, possibly because they were based on RNA isolated from whole-tumor homogenates, which would mix and obscure underlying diversity. The presence of this diversity suggests that there is considerable plasticity during tumor progression and presumably regions with different characteristics would compete for dominance and eventually the most aggressive or poorly differentiated area would prevail. Well-differentiated DCIS may progress to more poorly differentiated DCIS by this general mechanism. The magnitude of intratumor diversity observed in this study at all levels evaluated (histologic grade, biomarkers, and intrinsic subtypes) must be the lowest possible

Table 1. Histologic and biological diversity within individual cases of ductal carcinoma *in situ* ($n = 112$)

	N-Grade	ER	GATA3	erbB2	CK5/6	CK18	p53
Cases with diversity	48.2%	6.3%	1.8%	7.1%	7.1%	0.9%	5.4%
Type of Diversity	% Cases	% ER+		% erbB2+		% p53+	
None	51.8%	70.7%	$P = 0.2833$	39.7%	$P = 0.9296$	13.8%	$P = 0.0007$
N-Grade	48.2%	60.8%		39.2%		40.5%	
N-Grade + biomarker	13.4%	57.6%		57.6%		45.5%	

estimate of the true diversity in DCIS, because such a small (<1%) volume of tumor was evaluated in these experiments and there is probably more than enough to account for the broad continuum of diversity observed between cases overall. It seems likely that similar intratumor diversity exists and evolves in IBCs as well.

Other evidence supporting the idea that higher-grade DCIS evolve from lower-grade DCIS comes from studies showing that diversity increases with time. For example, a diagnosis of DCIS was rare (<5%) before but common (20-30%) after the introduction of screening mammography (49, 50). On average, DCIS were larger and more poorly differentiated in the premammography era than they are today (50–53), which is also true for IBCs (50, 52, 54). For example, in this study, the average conventional histologic score/grade of the series of DCIS in Fig. 1 (diagnosed between 1980 and 1995) and Fig. 3 (diagnosed between 1996 and 2002) were 8.4/2.0 and 7.2/1.6, respectively ($P = 0.0003$). Screening mammography became routine in our hospitals in the late 1980s, and thus, the first series contained a substantial number of cases that were not detected by mammography whereas cases in the second series nearly all were. The significant decrease in histologic score/grade observed in the second series is consistent with the idea that early detection due to screening mammography identified lower-grade tumors before they progressed to higher-grade lesions.

A similar conclusion can be drawn from studies showing that DCIS contain many of the same specific genetic defects regardless of histologic differentiation, although the absolute number of defects is higher in more poorly differentiated lesions. For example, previous studies from our laboratory (9) assessing loss of heterozygosity (LOH) in DCIS categorized into high grade and non-high grade showed similar frequencies of

LOH for the majority (80%) of the 15 cancer-associated loci evaluated, but there was a higher average number of LOH in the high-grade lesions (2.4/case versus 1.8/case; $P = 0.13$; Supplementary Fig. S2). Studies assessing chromosomal alterations by comparative genomic hybridization have also shown that high-grade and non-high-grade DCIS have many more similarities than differences in terms of specific defects (48). One of the loci in our LOH study spanned p53 (D17/s960 at 17p13), and DCIS with LOH at this locus showed significantly higher average LOH than those without (3.0 LOH/case versus 1.6 LOH/case; $P = 0.0001$). This is consistent with our immunohistochemistry results showing higher diversity in DCIS with mutated p53, further supporting the idea that defects leading to genetic instability promote diversity in DCIS, which, again, is a plausible mechanism for the progression of higher from lower-grade lesions.

There are two prominent hypotheses in current thinking about breast cancer evolution: the Wellings Jensen model emphasized in this paper proposes a prolonged evolution of worsening precursor lesions through the random accumulation of genetic mutations (1, 2), whereas the other proposes that subtypes of tumors arise through the expansion of categorical stem or progenitor cells, which may then also undergo mutations (55, 56). Both theories are based on compelling and reproducible observations, and, in our opinion, they are not intrinsically incompatible. For example, perhaps cancer stem cells are created from normal stem cells which slowly acquire and accumulate random mutations, explaining the prominent intratumor diversity and decades-long premalignant evolution proposed by Wellings and Jensen. The same mutation might have different consequences depending on the stage of commitment of the stem or progenitor cell it occurs in.

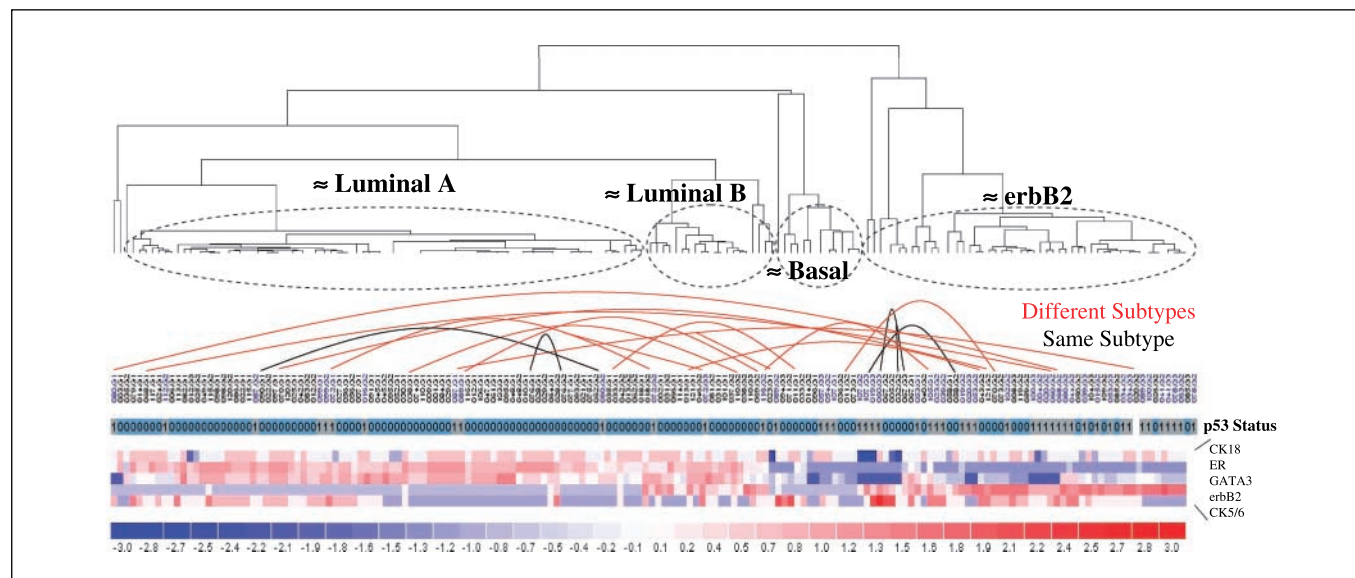


Fig. 5. Diversity of intrinsic subtypes within cases of pure DCIS. Recent consecutive cases of pure DCIS ($n = 112$) were evaluated for the presence of cells showing different histologic nuclear grades comprising at least 5% of cells within the same tumor. The cases were also evaluated by immunohistochemistry for protein expression of several biomarkers associated with each nuclear grade within each case, including ER, GATA3, erbB2, CK5/6, CK18, and p53. Assessing these particular biomarkers by immunohistochemistry has been shown to be reasonably equivalent to DNA microarrays for identifying intrinsic subtypes in IBCs. As expected, an unsupervised hierarchical clustering of the immunohistochemistry results segregated the DCIS into groups consistent with luminal A, luminal B, basal, and erbB2 intrinsic subtypes. In this analysis, regions showing different nuclear grades and their associated biomarker phenotypes within individual tumors were treated as separate tumors. A large majority (73%) of cases with diversity of nuclear grade and biomarkers also showed diversity of intrinsic subtypes (>1 subtype per case) of nearly all possible combinations (luminal A + erbB2 = 4; luminal A + basal = 1; luminal A + luminal B = 3; luminal B + erbB2 = 2; erbB2 + basal = 1).

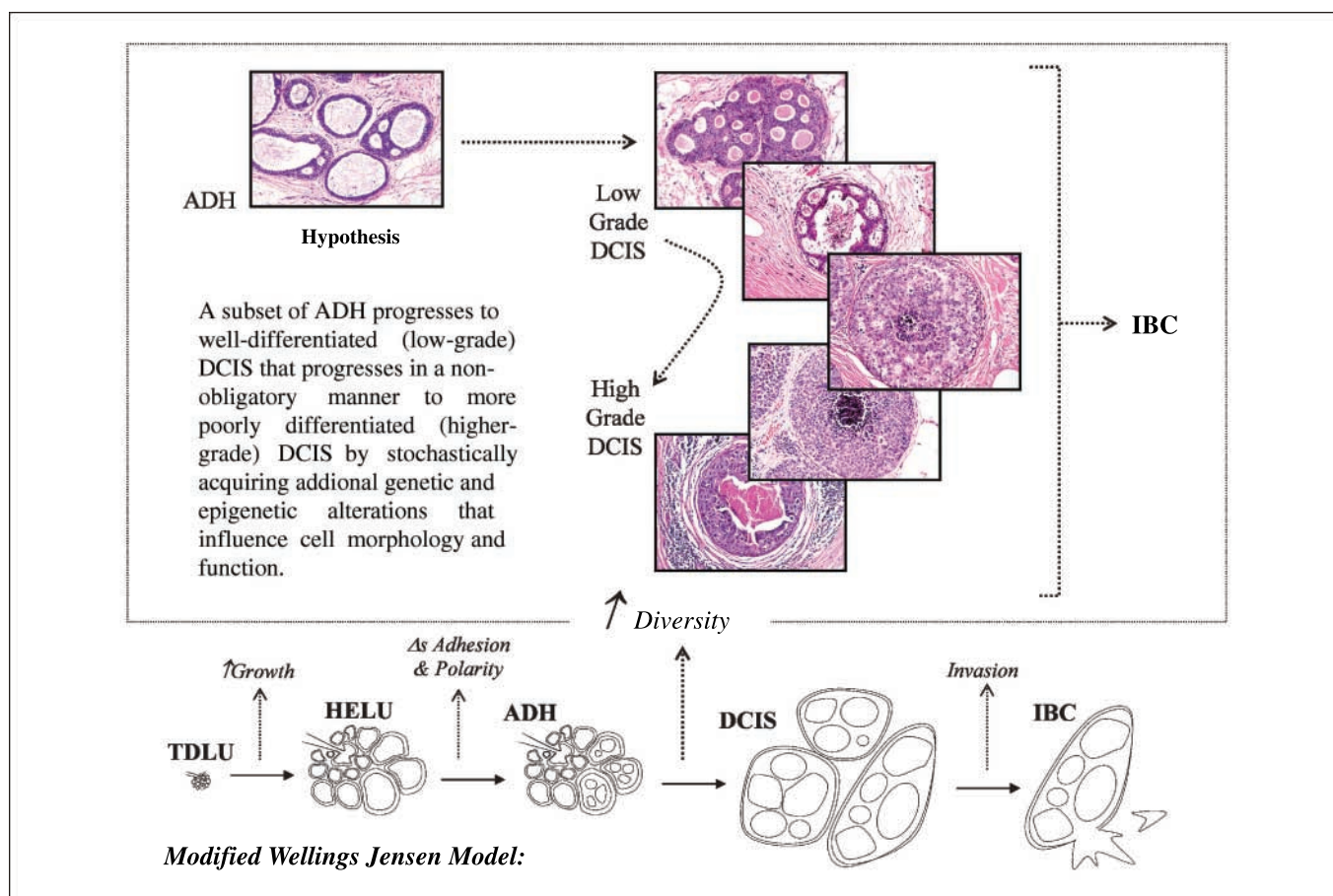


Fig. 6. Revised Wellings and Jensen model of human breast cancer evolution. The original Wellings and Jensen model proposed an apparently continuous but nonobligatory linear progression from normal TDLUs to IBC through a series of increasingly abnormal stages over long periods of time. Although it is artificial to define stages in a continuum, there are important general characteristics distinguishing one from another that accumulate and increase with progression. For example, the transition from TDLUs to HELUs is characterized by increased growth. Alterations of epithelial adhesion and polarity distinguish ADH from HELUs as the cells begin to pile up and distend acini. DCIS are characterized by expansion of tumor volume, intraductal spread into adjacent areas of the breast, and, most importantly, the appearance of enormous histologic and biological diversity. Invasion into surrounding stroma defines the transition of DCIS to IBC. The results of this study and other often overlooked evidence support the hypothesis that many higher-grade DCIS gradually evolve from lower-grade DCIS and, thus, indirectly from ADH by the stochastic accumulation of genetic defects which result in increasingly abnormal cellular morphology and function, that this diversity is greatly accelerated and magnified by defects resulting in genetic instability, and that the diversity is propagated to IBC in a manner that is largely independent of progression to invasion.

Mutations in an early multipotential stem cell might result in more diverse and rapidly evolving tumors than defects in a more committed progenitor cell. Alternatively, perhaps cancer stem cells can be newly created from somatic cells by mutations which reactivate genes regulating stem cell behavior (self-renewal and multipotential differentiation). Furthermore, creating cancer stem cells by mutating normal stem cells or by reactivating stem cell properties in somatic cells are not mutually exclusive possibilities, and both could help explain the enormous biological diversity observed within and between breast cancers. Some cancers may even contain multiple stem

cells, contributing to intratumor diversity. Even genetically transformed somatic cells without stem cell properties may have the potential to create a mass large enough to be potentially lethal.

If it is true that most breast cancers evolve from precursors which gradually change over time, then identifying biological alterations associated with early precursors before the development of substantial diversity may reveal effective strategies for the prevention of the majority of breast cancers, independent of differentiation. Hopefully, future studies will shed light on these important issues.

References

- Wellings RR, Jensen HM. On the origin and progression of ductal carcinoma in the human breast. *J Natl Cancer Inst* 1973;50:1111–8.
- Wellings SR, Jensen HM, Marcum RG. An atlas of subgross pathology of the human breast with special reference to possible precancerous lesions. *J Natl Cancer Inst* 1975;55:231–73.
- Allred DC, Hilsenbeck SG, Mohsin SK. Biologic features of human premalignant breast disease. In: Harris JR, Lippman ME, Morrow M, et al., editors. *Diseases of the Breast*. Philadelphia: Lippincott Williams & Wilkins; 2004. p. 512–3.
- Lee S, Mohsin SK, Mao S, et al. Hormones, receptors, and growth in hyperplastic enlarged lobular units: early potential precursors of breast cancer. *Breast Cancer Res* 2006;8:R6.
- Page DL, Simpson JF. Pathology of preinvasive and excellent-prognosis breast cancer. *Curr Opin Oncol* 2000;12:526–31.
- Schnitt SJ. Benign breast disease and breast cancer risk: morphology and beyond. *Am J Surg Pathol* 2003;27:836–41.
- Shaaban AM, Sloane JP, West CR, et al. Histopathologic types of benign breast lesions and the risk of

- breast cancer: case-control study. *Am J Surg Pathol* 2002;26:421–30.
8. Moirfar F, Man Y-G, Bratthauer GL, et al. Genetic abnormalities in mammary intraepithelial neoplasia-flat type ("cloning ductal carcinoma *in situ*"): a simulator of normal mammary epithelium. *Cancer* 2000;88:2072–81.
 9. O'Connell P, Pekkel V, Fuqua SAW, et al. Analysis of loss of heterozygosity in 399 premalignant breast lesions at 15 genetic loci. *J Natl Cancer Inst* 1998;90:697–703.
 10. Simpson PT, Gale T, Reis-Filho JS, et al. Columnar cell lesions of the breast: the missing link in breast cancer progression? A morphological and molecular analysis. *Am J Surg Pathol* 2005;29:734–46.
 11. Cardiff RD. Genetically engineered mouse models of mammary intraepithelial neoplasia. *J Mammary Gland Biol Neoplasia* 2000;5:421–37.
 12. Medina D. The preneoplastic phenotype in murine mammary tumorigenesis. *J Mammary Gland Biol Neoplasia* 2000;5:393–407.
 13. Miller FR. Xenograft models of premalignant breast disease. *J Mammary Gland Biol Neoplasia* 2000;5:379–91.
 14. Page DL, Dupont WD, Rogers LW, et al. Atypical hyperplastic lesions of the female breast. A long-term follow-up study. *Cancer* 1985;55:2698–708.
 15. Moreno A, Lloveras B, Figueras A, et al. Ductal carcinoma *in situ* of the breast: correlation between histological classifications and biologic markers. *Mod Pathol* 1997;10:1088–92.
 16. Scott MA, Lagios MD, Axelsson K, et al. Ductal carcinoma *in situ* of the breast: reproducibility of histological subtype analysis. *Hum Pathol* 1997;28:967–73.
 17. Shocker BS, Jarvis C, Clarke RB, et al. Estrogen receptor-positive proliferating cells in the normal and precancerous breast. *Am J Pathol* 1999;155:1811–5.
 18. Silverstein MJ, Cohlan BF, Gierson ED, et al. Duct carcinoma *in situ*: 227 cases without microinvasion. *Eur J Cancer* 1992;28:630–4.
 19. Elston CW, Ellis IO. Pathological prognostic factors in breast cancer: I. The value of histological grade in breast cancer: experience from a large study with long-term follow-up. *Histopathology* 1991;19:403–10.
 20. Elston EW, Ellis IO. Method for grading breast cancer. *J Clin Pathol* 1993;46:189–90.
 21. Fisher ER, Gregorio RM, Fisher B. The pathology of invasive breast cancer: a syllabus derived from the findings of the National Surgical Adjuvant Breast Project (protocol 4). *Cancer* 1975;36:1–85.
 22. Allred DC, Clark GM, Elledge RM, et al. Accumulation of mutant p53 is associated with increased proliferation and poor clinical outcome in node-negative breast cancer. *J Natl Cancer Inst* 1993;85:200–6.
 23. Elledge RM, Gray R, Mansour E, et al. Accumulation of p53 protein as a possible predictor of response to adjuvant combination chemotherapy with cyclophosphamide, methotrexate, fluorouracil, and prednisone for breast cancer. *J Natl Cancer Inst* 1995;87:1254–6.
 24. Harvey JM, Clark GM, Osborne CK, et al. Estrogen receptor status by immunohistochemistry is superior to the ligand-binding assay for predicting response to adjuvant endocrine therapy in breast cancer. *J Clin Oncol* 1999;17:1474–81.
 25. Love RR, Duc NB, Havighurst TC, et al. HER-2/neu overexpression and response to oophorectomy plus tamoxifen adjuvant therapy in estrogen receptor-positive premenopausal women with operable breast cancer. *J Clin Oncol* 2003;21:453–7.
 26. Mohsin SK, Clark GM, Havighurst T, et al. Progesterone receptor by immunohistochemistry and clinical outcome in breast cancer: a validation study. *Mod Pathol* 2004;17:1545–54.
 27. Allred DC, Harvey JM, Berardo MD, et al. Prognostic and predictive factors in breast cancer by immunohistochemical analysis [review]. *Mod Pathol* 1998;11:155–68.
 28. Livasy CA, Karaca G, Nanda R, et al. Phenotypic evaluation of the basal-like subtype of invasive breast carcinoma. *Mod Pathol* 2006;19:264–71.
 29. Livasy CA, Perou CM, Karaca G, et al. Identification of a basal-like subtype of breast ductal carcinoma *in situ*. *Hum Pathol* 2007;38:197–204.
 30. Nielsen TO, Hsu FD, Jensen K, et al. Immunohistochemical and clinical characterization of the basal-like subtype of invasive breast carcinoma. *Clin Cancer Res* 2004;10:5367–74.
 31. Eberwine J. Amplification of mRNA populations using aRNA generated from immobilized oligo(dT)-T7 primed cDNA. *Biotechniques* 1996;20:584–91.
 32. Phillips J, Eberwine JH. Antisense RNA Amplification: a linear amplification method for analyzing the mRNA population from single living cells. *Methods* 1996;10:283–8.
 33. Perou CM, Sorlie T, Eisen MB, et al. Molecular portraits of human breast tumours. *Nature* 2000;406:747–52.
 34. Sorlie T, Perou CM, Tibshirani R, et al. Gene expression patterns of breast carcinomas distinguish tumor subclasses with clinical implications. *Proc Natl Acad Sci U S A* 2001;98:10869–74.
 35. Sorlie T, Tibshirani R, Parker J, et al. Repeated observation of breast tumor subtypes in independent gene expression data sets. *Proc Natl Acad Sci U S A* 2003;100:8418–23.
 36. Jacobs TW, Byrne C, Colditz G, et al. Pathologic features of breast cancers in women with previous benign breast disease. *Am J Clin Pathol* 2001;115:362–9.
 37. Gupta SK, Douglas-Jones AG, Morgan JM, et al. The clinical behavior of breast carcinoma is probably determined at the preinvasive stage (ductal carcinoma *in situ*). *Cancer* 1997;80:1740–5.
 38. Leong AS, Sormunen RT, Vinyuvat S, et al. Biologic markers in ductal carcinoma *in situ* and concurrent infiltrating carcinoma. A comparison of eight contemporary grading systems. *Am J Clin Pathol* 2001;115:709–18.
 39. Mack L, Kerkvliet N, Doig G, et al. Relationship of a new histological categorization of ductal carcinoma *in situ* of the breast with size and the immunohistochemical expression of p53, c-erb B2, bcl-2, and ki-67. *Hum Pathol* 1997;28:974–9.
 40. Ottesen GL, Christensen IJ, Larsen JK, et al. Carcinoma *in situ* of the breast: correlation of histopathology to immunohistochemical markers and DNA ploidy. *Breast Cancer Res Treat* 2000;60:219–26.
 41. Solin LJ, Kurtz J, Fourquet A, et al. Fifteen-year results of breast-conserving surgery and definitive breast irradiation for the treatment of ductal carcinoma *in situ* of the breast. *J Clin Oncol* 1996;14:754–63.
 42. Hannemann J, Velds A, Halfwerk JB, et al. Classification of ductal carcinoma *in situ* by gene expression profiling. *Breast Cancer Res* 2006;8:R61.
 43. Ma XJ, Salunga R, Tuggle JT, et al. Gene expression profiles of human breast cancer progression. *Proc Natl Acad Sci U S A* 2003;100:5974–9.
 44. Porter D, Lahti-Domenici J, Keshaviah A, et al. Molecular markers in ductal carcinoma *in situ* of the breast. *Mol Cancer Res* 2003;1:362–75.
 45. Lennington WJ, Jensen RA, Dalton LW, et al. Ductal carcinoma *in situ* of the breast. Heterogeneity of individual lesions. *Cancer* 1994;73:118–24.
 46. Baas IO, Mulder JW, Offerhaus GJ, et al. An evaluation of six antibodies for immunohistochemistry of mutant p53 gene product in archival colorectal neoplasms. *J Pathol* 1994;172:5–12.
 47. Perez-Losada J, Mao JH, Balmain A. Control of genomic instability and epithelial tumor development by the p53–7/Cdc4 pathway. *Cancer Res* 2005;65:6488–92.
 48. Hwang ES, DeVries S, Chew KL, et al. Patterns of chromosomal alterations in breast ductal carcinoma *in situ*. *Clin Cancer Res* 2004;10:5160–7.
 49. Ernster VL, Barclay J. Increases in ductal carcinoma *in situ* (DCIS) of the breast in relation to mammography: a dilemma. *J Natl Cancer Inst Monogr* 1997;22:151–6.
 50. Ries LAG, Eisner MP, Kosary CL. SEER Cancer Statistics Review 1975–2000. Bethesda: National Cancer Institute; 2003.
 51. Allred DC, Clark GM, Molina R, et al. Overexpression of HER-2/neu and its relationship with other prognostic factors change during the progression of *in situ* to invasive breast cancer. *Hum Pathol* 1992;23:974–9.
 52. American Cancer Society: Breast Cancer Facts and Figures 2005–2006. Atlanta: American Cancer Society, Inc.; 2005.
 53. van de Vijver MJ, Peterse JL, Mooi WJ, et al. Neu-protein overexpression in breast cancer. Association with comedo-type ductal carcinoma *in situ* and limited prognostic value in stage II breast cancer. *N Engl J Med* 1988;319:1239–45.
 54. Magne N, Roillon RA, Castadot P, et al. Different clinical impact of estradiol receptor determination according to the analytical method: a study on 1940 breast cancer patients over a period of 16 consecutive years. *Breast Cancer Res Treat* 2006;95:179–84.
 55. Dontu G, Liu S, Wicha MS. Stem cells in mammary development and carcinogenesis: implications for prevention and treatment. *Stem Cell Rev* 2005;1:207–13.
 56. Liu S, Dontu G, Wicha MS. Mammary stem cells, self-renewal pathways, and carcinogenesis. *Breast Cancer Res* 2005;7:86–95.

Is Breast Tumor Progression Really Linear?

□□ *Commentary on Allred et al., p. 370*

Kornelia Polyak

"Progress has not followed a straight ascending line, but a spiral with rhythms of progress and retrogression, of evolution and dissolution."

Johann Wolfgang Von Goethe

In real life, most of us are likely to agree with this quote from Goethe. Yet, our generally accepted view of tumor progression depicts a linear route going from a normal cell to a metastatic tumor driven by progressively accumulating genetic, epigenetic, and microenvironmental alterations. Tumorigenesis has been described as an evolutionary process decades ago (1, 2), but still very few molecular studies have even attempted to analyze tumor progression from a population biology point of view. This is in part due to our relentless desire to view the world through a "simplifier glass" and in part due to the technical difficulties associated with these types of studies. Analyzing tumors not just as a ground-up bulk tissue, but as a population of individual tumor cells, requires the dissection of molecular differences at the single cell level or at least in homogenous cell populations. In this issue of *Clinical Cancer Research*, Allred et al. (3) have taken on the challenging task of evaluating intertumoral and intratumoral diversity in ductal carcinoma *in situ* (DCIS) of the breast using various approaches.

The currently accepted view of breast tumor progression assumes the gradual step-by-step transition of ductal hyperproliferation to *in situ* then invasive and eventually metastatic carcinomas (Fig. 1; refs. 4–6). Thus, DCIS is considered the obligate precursor of invasive ductal carcinomas (7). This tumor progression model is strongly supported by epidemiologic, pathologic/clinical, and molecular data obtained in human breast cancer patients as well as in animal models. Premalignant tumors, including DCIS, are more frequently observed in women with a high risk of breast cancer and they are frequently located adjacent to invasive carcinomas (8, 9). In addition, molecular studies have shown clonal relationships between tumors of different stages including DCIS and adjacent invasive cancer and DCIS and its invasive recurrence (10, 11).

Author's Affiliation: Department of Medical Oncology, Dana-Farber Cancer Institute, and Department of Medicine, Harvard Medical School and Brigham and Women's Hospital, Boston, Massachusetts

Grant support: National Cancer Institute (CA89393, CA94074, and CA116235), Department of Defense (W81XWH-07-1-0294), Avon Foundation, and American Cancer Society (RSG-05-154-01-MGO).

Conflict of interest: The author receives research support from and is a consultant to the Novartis Institute of Biomedical Research, and is also a consultant to AVEO Pharmaceuticals.

Requests for reprints: Kornelia Polyak, Department of Medical Oncology, Dana-Farber Cancer Institute, and Department of Medicine, Harvard Medical School and Brigham and Women's Hospital, 44 Binney Street, Boston, MA 02115. Phone: 617-632-2106; E-mail: kornelia.polyak@dfci.harvard.edu.

©2008 American Association for Cancer Research.

doi:10.1158/1078-0432.CCR-07-2188

Breast cancer has long been recognized as a heterogeneous disease with varying clinical outcome. This intertumoral heterogeneity was dramatically shown by recent molecular profiling studies clustering the tumors into distinct luminal, HER2, and basal-like subtypes based on their global gene expression patterns (12, 13). Luminal tumors are more differentiated, hormone receptor-positive, and in general, have better outcome. HER2+ tumors have amplification of the ERBB2 oncogene and respond to therapy targeting this receptor kinase. Basal-like tumors are poorly differentiated, lack hormone receptors and HER2, and in general, tend to have worse clinical outcome because of their propensity to develop distant metastases and lack of targeted therapy against them. Just as this new molecular classification system was established, however, it also became apparent that tumors within each subtype are still fairly heterogeneous with respect to clinical outcome and that some tumors do not fit into any of these major molecular subgroups. Thus, even this molecular-based classification is oversimplifying reality and further refinements are necessary.

To address intertumoral heterogeneity in DCIS at the molecular level, Allred and colleagues (3) analyzed histologic differentiation and commonly used prognostic biomarkers including hormone receptors (estrogen receptor and progesterone receptor), HER2, p53, and cell proliferation (Ki67 expression) in pure DCIS, DCIS adjacent to invasive cancer, and in invasive ductal carcinomas (200 cases of each tumor type). A subset of DCIS cases were also analyzed for global gene expression profiles. Overall, the distribution of histologic differentiation grades and their association with prognostic markers were the same in DCIS, DCIS adjacent to invasive ductal carcinoma, and in invasive ductal carcinoma. Correlating with previous data, well-differentiated tumors were more frequently hormone receptor-positive (estrogen receptor-positive and progesterone receptor-positive) and negative for HER2, p53, and Ki67 compared with poorly differentiated tumors. Unsupervised clustering of 25 DCIS tumors also identified the same luminal, basal, and HER2+ subtypes as has been previously reported in both invasive and *in situ* breast carcinomas (12, 14).

When the researchers further refined their analysis to address intratumoral heterogeneity at the cellular level, however, they found that about half of the tumors were phenotypically highly diverse. This was true for histologic differentiation grades (e.g., the same DCIS show poorly and well-differentiated areas) as well as for the expression of several biomarkers analyzed (ER, HER2, GATA3, CK5/6, CK18, and p53). Furthermore, the expression of p53 (reflecting mutant p53) was statistically significantly correlated with the presence and extent of this phenotypic diversity. Molecular classification studies have suggested that distinct breast cancer subtypes might have distinct cells of origin and tumor progression pathways. The data presented by Allred and colleagues (3) indicates that this

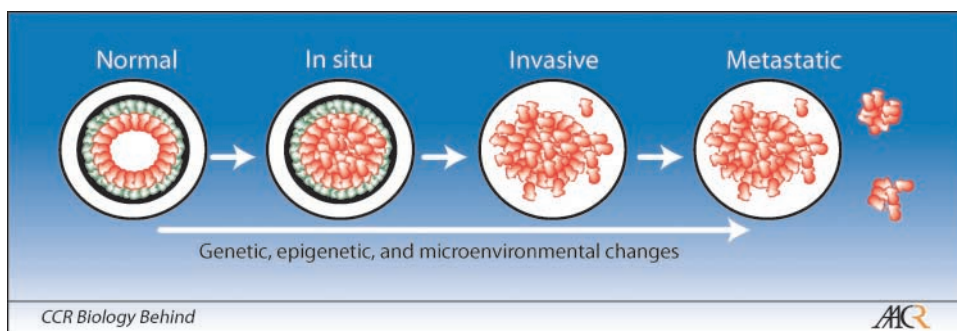


Fig. 1. Schematic outline of breast tumor progression. Tumorigenesis goes through defined histologic and clinical stages and is driven by progressively accumulating genetic, epigenetic, and microenvironmental alterations. Thin and thick black circles indicate the breast and the basement membrane surrounding the ducts, respectively. Myoepithelial/basal cells (*green cells*) synthesize and are in direct contact with the basement membrane, whereas luminal epithelial cells (*red cells*) lay on top of the myoepithelium. A major distinguishing feature of the *in situ* to invasive carcinoma transition is the disappearance of the basement membrane and the myoepithelial cell layer.

may not be so simple and generally true, however, as multiple tumor subtypes apparently frequently coexist within the same tumor. What is the reason for this intratumoral heterogeneity and what are its potential clinical implications?

Two of the currently prevailing models explaining intratumoral heterogeneity are the cancer stem cell and the clonal evolution hypotheses. According to the cancer stem cell hypothesis, a subset of cancer cells have the characteristics of stem cells and could give rise to progeny with different differentiation states (15, 16). The clonal evolution model, on the other hand, explains heterogeneity as a consequence of genomic instability, resulting in the continuous acquisition of new somatic changes, combined with the clonal selection for tumor cells with the most beneficial phenotype (1, 2, 17). In principle, both of these models are in agreement with the observations reported by Allred et al. (1). A limitation of the cancer stem cell hypothesis, however, is that it restricts the

tumor progression driving events to the cancer stem cells, which does not seem to be advantageous from a tumor evolutionary point of view and cannot explain certain clinical data, such as the emergence of drug-resistant clones after treatment. In evolutionary algorithms, the fitness of a population increases with time by mutating and recombining individuals and by a biased selection of more fit individuals. The right selection pressure is critical in ensuring sufficient optimization progress and in preserving genetic diversity to be able to escape from local optima. How can we translate this knowledge in evolutionary biology and population genetics into tumor biology? How can we measure diversity within human tumors, and most importantly, what is the clinical relevance of intratumoral diversity?

The most comprehensive study addressing these issues in human tumors was conducted by Maley and colleagues focusing on a premalignant lesion known as Barrett's esophagus (18).

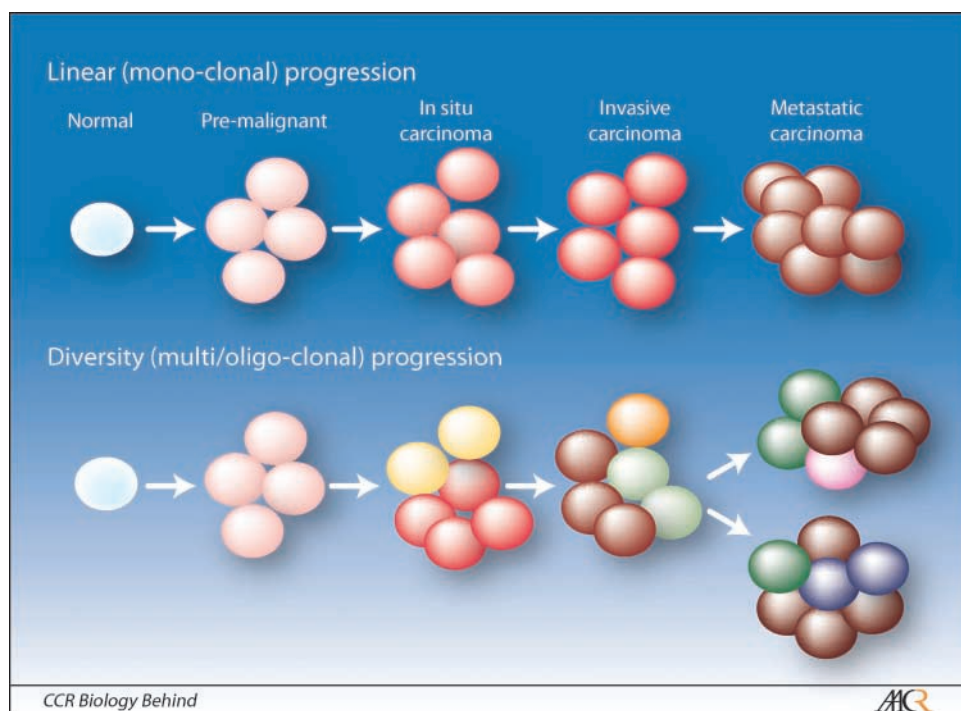


Fig. 2. Models of breast tumor progression. The linear evolution model proposes that there is a dominant tumor cell clone that progressively accumulates genetic and epigenetic alterations and it has growth and survival advantage due to environmental selection pressure. The diversity evolution model, on the other hand, proposes that although there could be a predominant clone within tumors, there are multiple other clones present as well. Depending on the selection conditions provided by the environment or therapeutic interventions, the identity of the dominant clone may change as tumors progress. As a consequence, heterogeneous tumors with higher clonal diversity are more likely to progress and develop resistance to treatment. Different color circles indicate distinct clones, whereas darkening intensity of the color reflects changes in the same clone (e.g., pink → red → dark red circles).

They dissected these premalignant lesions into 1-cm pieces and analyzed each of them independently for DNA content and genetic changes, including mutations in *TP53* and *CDKN2A* and loss of heterozygosity at multiple loci. Based on these comprehensive molecular profiles, and the principles of population biology, the researchers defined a clonal diversity score for each tumor and analyzed the associations of these scores with clinical outcome. The overall conclusion of the study was that higher clonal diversity predicts the risk of progression to invasive cancer. Thus, similar to what has been observed in ecological populations, diversity is beneficial for tumor progression as well. Furthermore, correlating with the findings of Allred et al. (1), diversity was statistically significantly associated with the presence of mutant p53.

Although Allred et al. (1) has not analyzed the genetic clonality within DCIS, immunohistochemical staining for HER2 and p53 is likely to reflect gene amplification and mutation, respectively. Thus, DCIS tumors may also be genetically diverse as has been observed in Barrett's esophagus

and this diversity may also correlate with the risk of progression to invasive cancer. Thus, instead of the simple linear view of breast tumor progression, we may have to consider a revised view that incorporates clonal diversity as one of the driving forces of progression (Fig. 2). Recent *in situ* analysis of genomic instability during breast tumor progression using fluorescence *in situ* hybridization has shown a dramatic increase in chromosomal aberrations in DCIS compared with ductal hyperplasia possibly caused by telomere shortening-induced crisis (19). Combined genotype-phenotype studies can be conducted in DCIS by using immuno-fluorescence *in situ* hybridization and genetic mutations can be analyzed by using DNA from cells purified with immuno-laser capture microdissection (20). Performing these studies in DCIS with long-term clinical outcome will allow the determination if the risk of progression correlates with a specific genetic alteration or with clonal diversity. Because all the tools are available, this author is sure that we do not have to wait long before we know the answers to these questions.

References

1. Nowell PC. The clonal evolution of tumor cell populations. *Science* 1976;194:23–8.
2. Vogelstein B, Kinzler KW. The multistep nature of cancer. *Trends Genet* 1993;9:138–41.
3. Allred DC, Wu Y, Mao S, et al. Ductal carcinoma *in situ* and the emergence of diversity during breast cancer evolution. *Clin Cancer Res* 2008;14:370–8.
4. Wellings SR, Jensen HM, Marcum RG. An atlas of subgross pathology of the human breast with special reference to possible precancerous lesions. *J Natl Cancer Inst* 1975;55:231–73.
5. Wellings SR, Jensen HM. On the origin and progression of ductal carcinoma in the human breast. *J Natl Cancer Inst* 1973;50:1111–8.
6. Simpson PT, Reis-Filho JS, Gale T, Lakhani SR. Molecular evolution of breast cancer. *J Pathol* 2005; 205:248–54.
7. Burstein HJ, Polyak K, Wong JS, Lester SC, Kaelin CM. Ductal carcinoma *in situ* of the breast. *N Engl J Med* 2004;350:1430–41.
8. Schnitt SJ. Benign breast disease and breast cancer risk: morphology and beyond. *Am J Surg Pathol* 2003;27:836–41.
9. Shaaban AM, Sloane JP, West CR, et al. Histopathologic types of benign breast lesions and the risk of breast cancer: case-control study. *Am J Surg Pathol* 2002;26:421–30.
10. Murphy DS, Hoare SF, Going JJ, et al. Characterization of extensive genetic alterations in ductal carcinoma *in situ* by fluorescence *in situ* hybridization and molecular analysis. *J Natl Cancer Inst* 1995;87:1694–704.
11. Lininger RA, Fujii H, Man YG, Gabrielson E, Tavassoli FA. Comparison of loss heterozygosity in primary and recurrent ductal carcinoma *in situ* of the breast. *Mod Pathol* 1998;11:1151–9.
12. Perou CM, Sorlie T, Eisen MB, et al. Molecular portraits of human breast tumours. *Nature* 2000;406:747–52.
13. Sorlie T, Perou CM, Tibshirani R, et al. Gene expression patterns of breast carcinomas distinguish tumor subclasses with clinical implications. *Proc Natl Acad Sci U S A* 2001;98:10869–74.
14. Yu K, Lee CH, Tan PH, Tan P. Conservation of breast cancer molecular subtypes and transcriptional patterns of tumor progression across distinct ethnic populations. *Clin Cancer Res* 2004;10:5508–17.
15. Reya T, Morrison SJ, Clarke MF, Weissman IL. Stem cells, cancer, and cancer stem cells. *Nature* 2001;414: 105–11.
16. Clarke MF, Fuller M. Stem cells and cancer: two faces of eve. *Cell* 2006;124:1111–5.
17. Merlo LM, Pepper JW, Reid BJ, Maley CC. Cancer as an evolutionary and ecological process. *Nat Rev Cancer* 2006;6:924–35.
18. Maley CC, Galipeau PC, Finley JC, et al. Genetic clonal diversity predicts progression to esophageal adenocarcinoma. *Nat Genet* 2006;38:468–73.
19. Chin K, de Solorzano CO, Knowles D, et al. *In situ* analyses of genome instability in breast cancer. *Nat Genet* 2004;36:984–8.
20. Buckanovich RJ, Sasaroli D, O'Brien-Jenkins A, et al. Use of immuno-LCM to identify the *in situ* expression profile of cellular constituents of the tumor microenvironment. *Cancer Biol Ther* 2006;5:635–42.