

Hemostasis and Thrombosis – Case Study

A 21 year old female college student comes to you with a two-day history of increasing shortness of breath and chest pain. History and physical examination reveal:

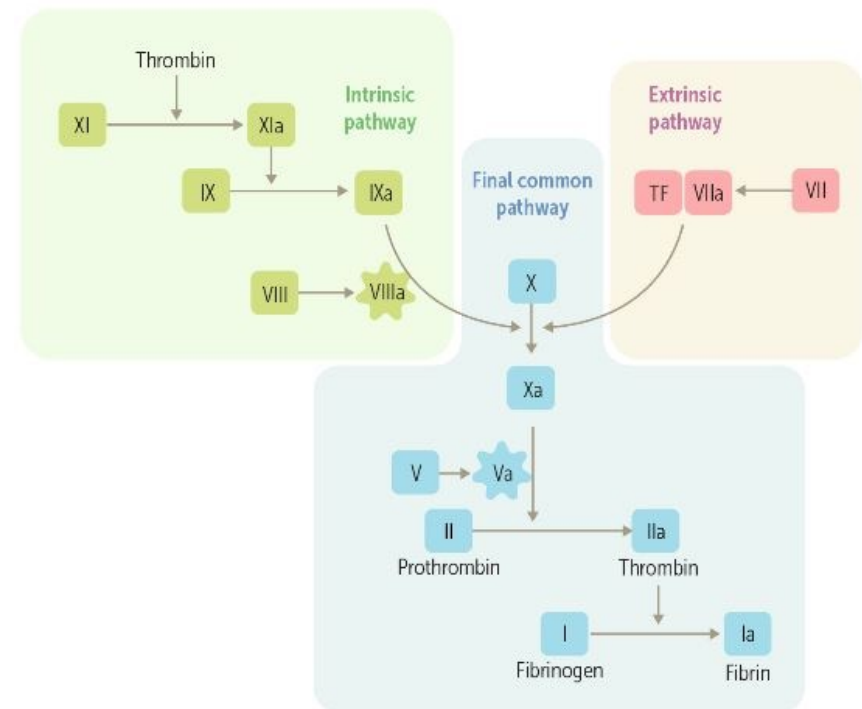
- she is an athlete, just returned from a softball tournament
- no significant prior medical history
- overweight
- tachypneic (breathing fast)
- tachycardic (high heart rate)
- no fever
- slight swelling of her left leg

Hemostasis and Thrombosis – Case Study

What lab tests do you want to order?

1. Prothrombin time: measures the function of the extrinsic pathway
2. Partial thromboplastin time: measures function of the intrinsic pathway
3. Fibrin degradation products: measures amount of circulating lysed fibrin
4. Platelet aggregation test: measures ability of platelets to clump together

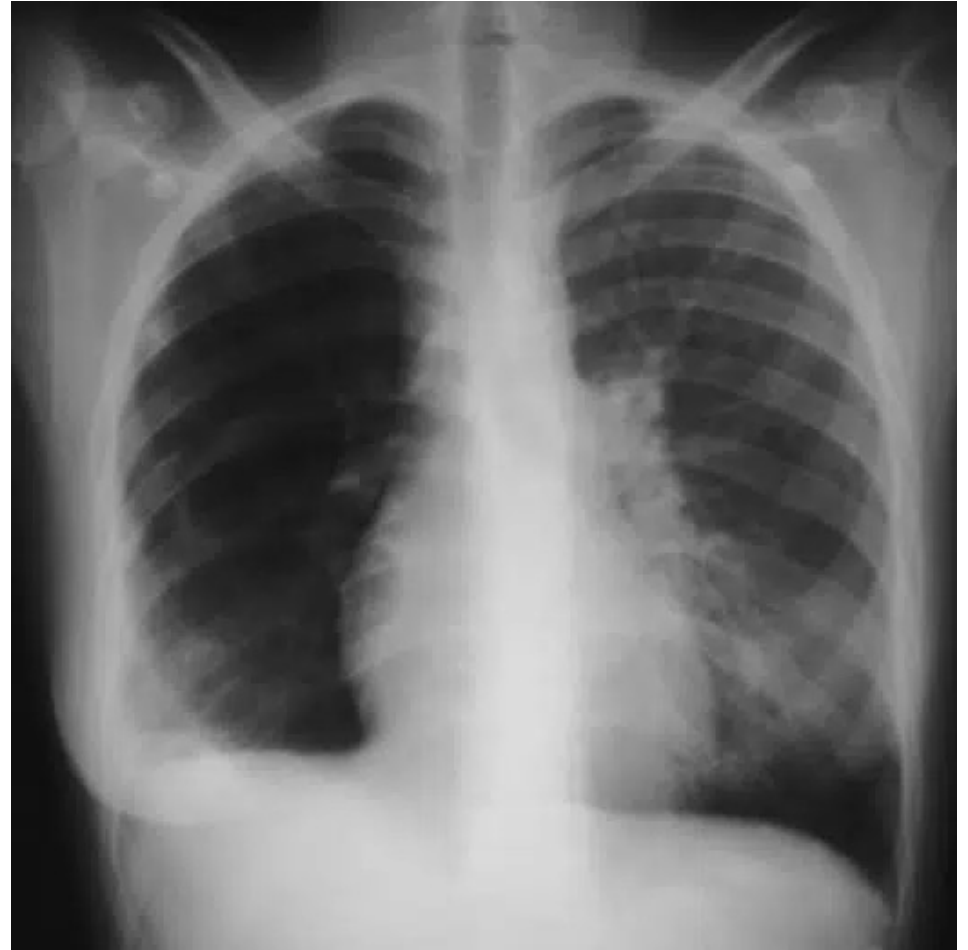What imaging test(s) do you want to order?



Hemostasis and Thrombosis – Case Study

You ordered a chest X-ray. It shows:

1. Several scattered opacifications near the lung periphery, especially in the lower lobes, and loss of vascular markings on the right side
2. Enlarged cardiac silhouette due to an enlarged right atrium



Hemostasis and Thrombosis – Case Study

- What additional questions do you want to ask her?
- What additional types of laboratory tests do you want to order?

Hemostasis and Thrombosis – Case Study

- You determine the patient is heterozygous for Factor V Leiden, a mutation that can make patients hypercoagulable and at risk for venous thrombosis. Risk factors for thrombosis include:
 - A family history of a blood clot in a vein deep in the body, called a deep vein thrombosis (DVT)
 - A history of DVT
 - Hormone therapy or birth control pills
 - Pregnancy
 - Injury to a vein, such as from surgery, a broken bone, or other trauma
 - Lack of movement, such as after surgery or on a long trip
 - Inherited blood clotting disorders
 - A central venous catheter
 - Older age
 - Smoking
 - Being overweight or obese
 - Some health conditions, such as cancer, heart disease, lung disease, or Crohn's disease