

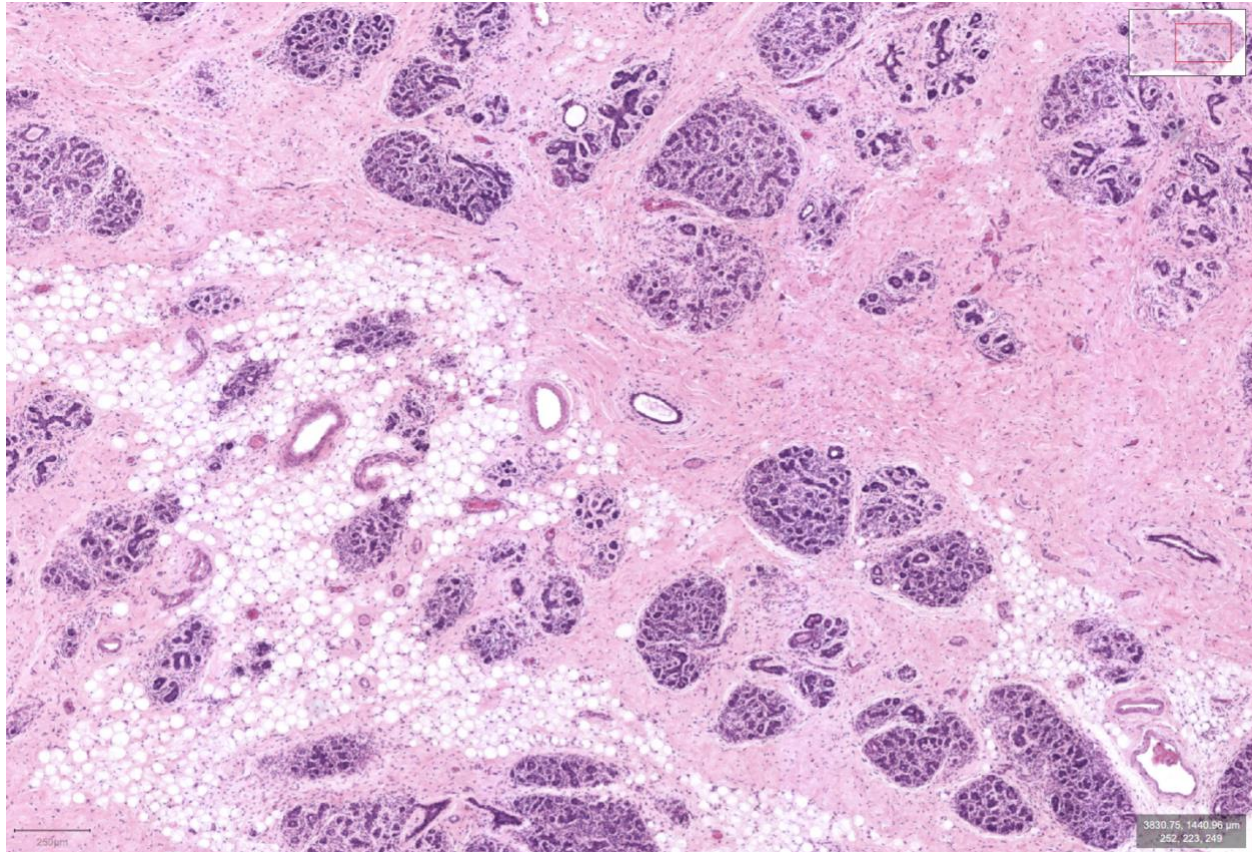
**Case Study #2, August 29, 2023**

A 55 year old female undergoing a routine mammogram is observed to have overall dense tissue in both breasts. Two areas of extremely dense tissue, one on the left breast and one on the right breast are concerning to the radiologist. Fine needle biopsies are ordered for both areas of concern.

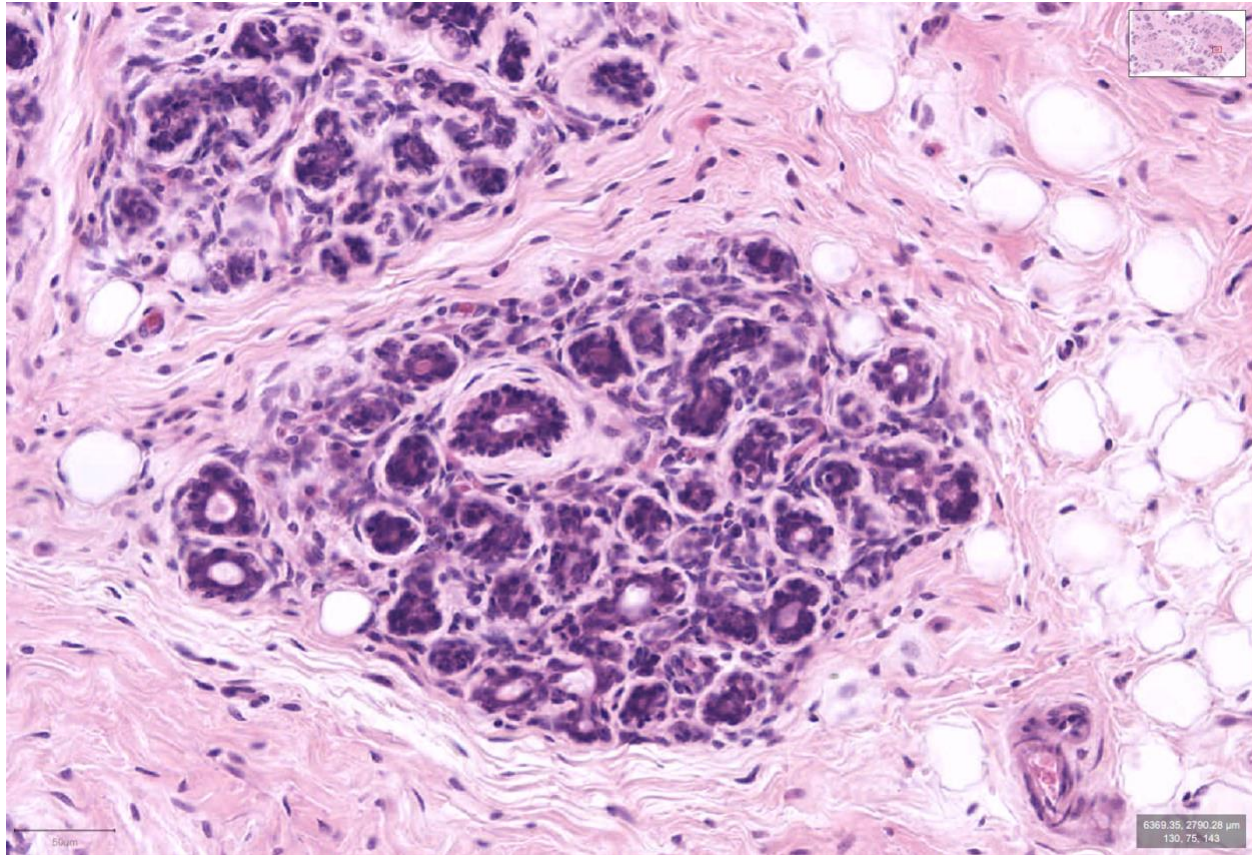
Following collection, what is the first thing that would happen to the collected tissue?

What are additional steps that would be taken for routine analysis?

Pictures from the standard staining process for the right breast sample are below:



Here is a zoomed in picture of the sample from the right breast:



Can you identify areas that may be epithelial tissue?

Can you identify areas that may be stromal tissue?

Are there adipose (fat) cells in the picture?

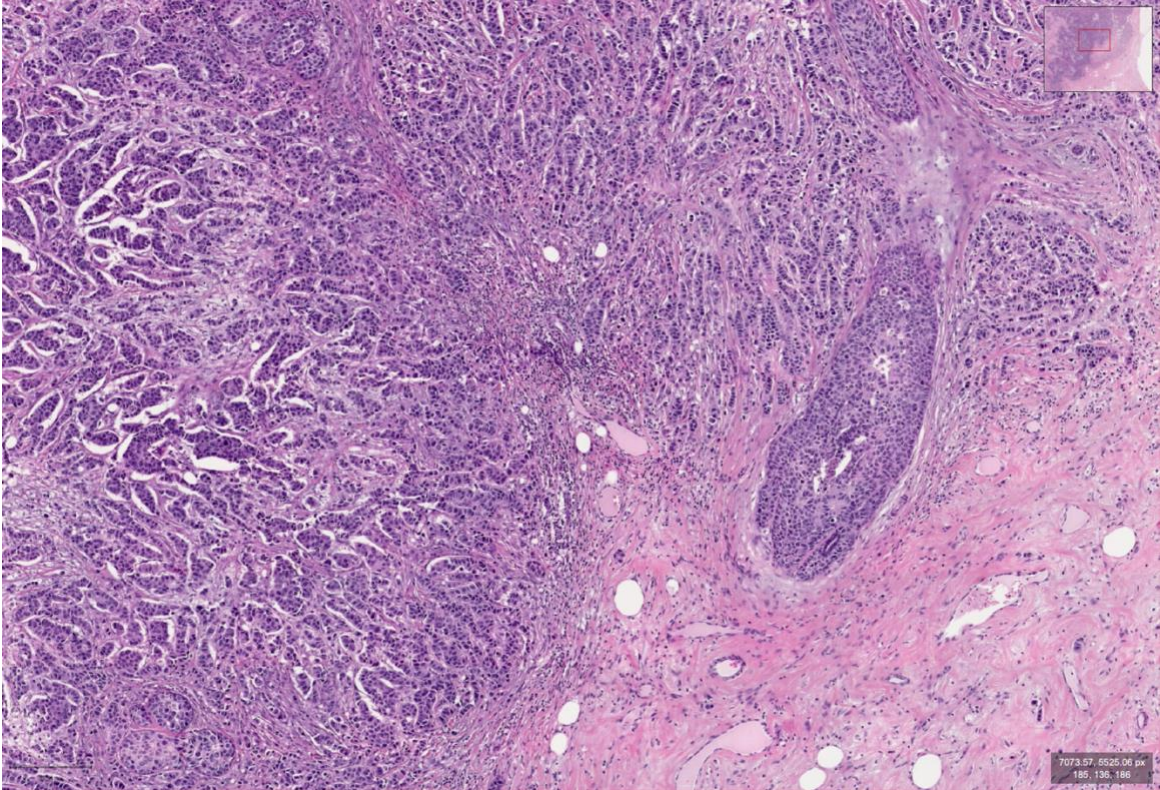
Do you see any blood vessels?

Do you think this tissue is diseased or normal?

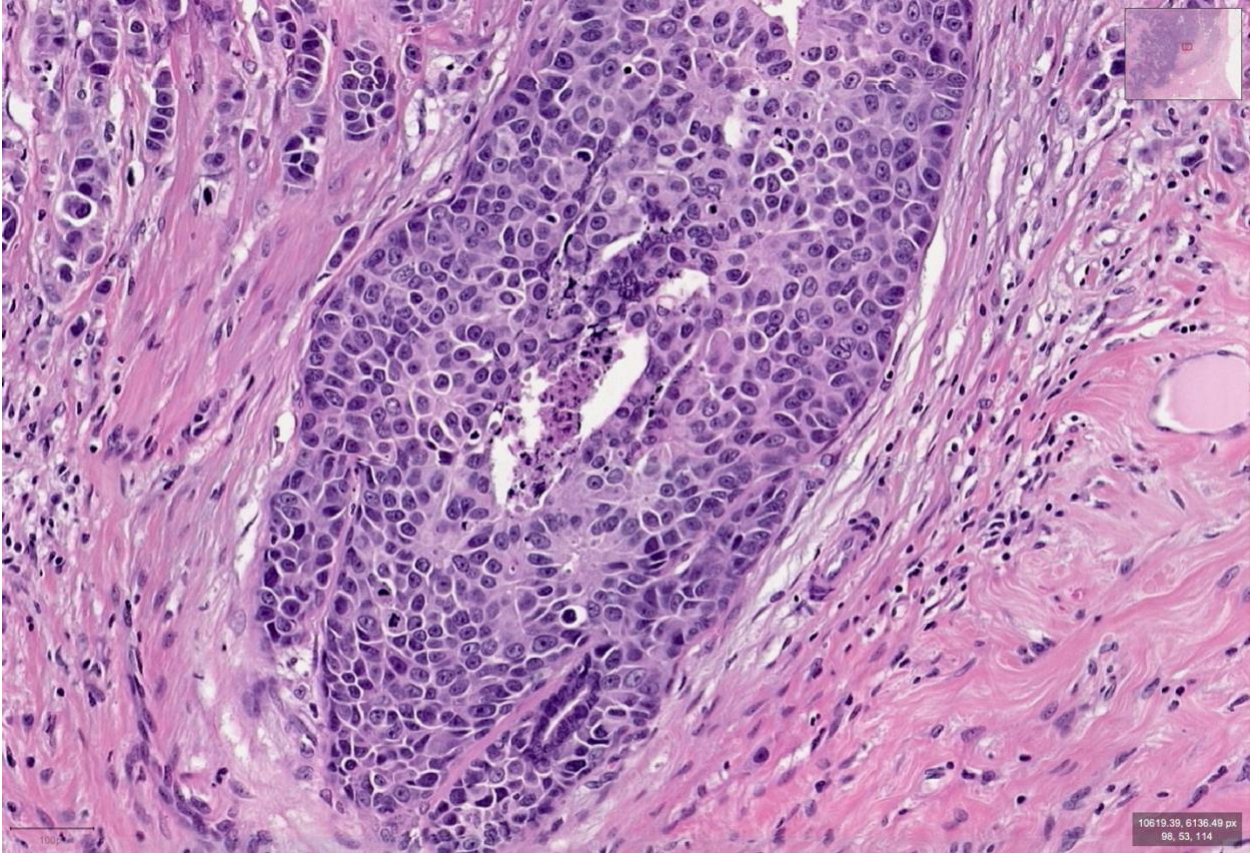
What are some characteristics that make you choose it being either diseased or normal tissue?



Pictures from the standard staining process for the left breast sample are below:



Here is a zoomed in picture of the sample from the left breast:



Can you identify areas that may be epithelial tissue?

Can you identify areas that may be stromal tissue?

Are there adipose (fat) cells in the picture?

Do you see any blood vessels?

Do you think this tissue is diseased or normal?

What are some characteristics that make you choose it being either diseased or normal tissue?