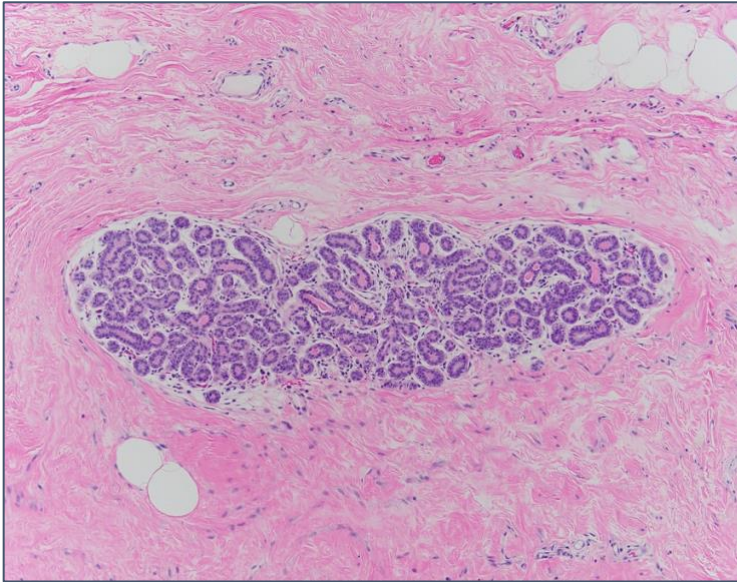


Case Study Cancer Biology Case Study

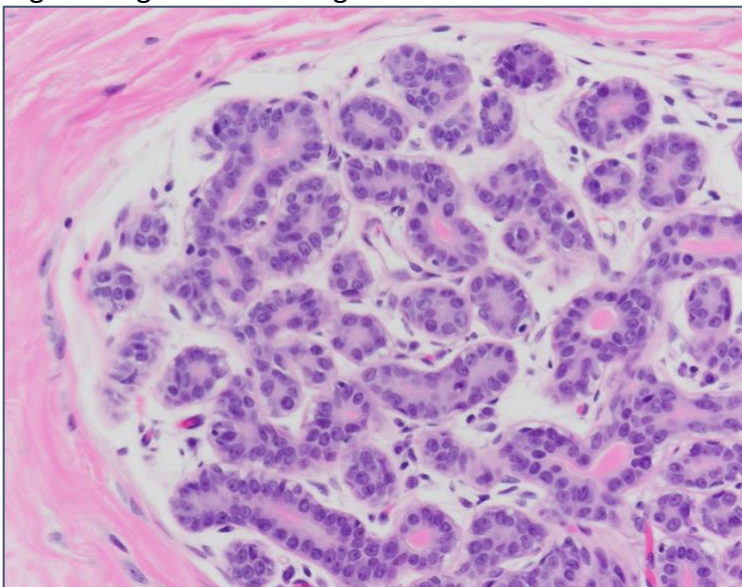
A 56 year-old female went in for regular mammogram screening. Screening showed increased breast density in the right breast and a 10 cm mass in the left breast. The patient was referred to a breast cancer center where a biopsy was obtained from both the right and left breast. Biopsy tissue was fixed, processed, embedded and sectioned.

What is the primary stain for these sections so the Pathologist (you) can examine the tissue?

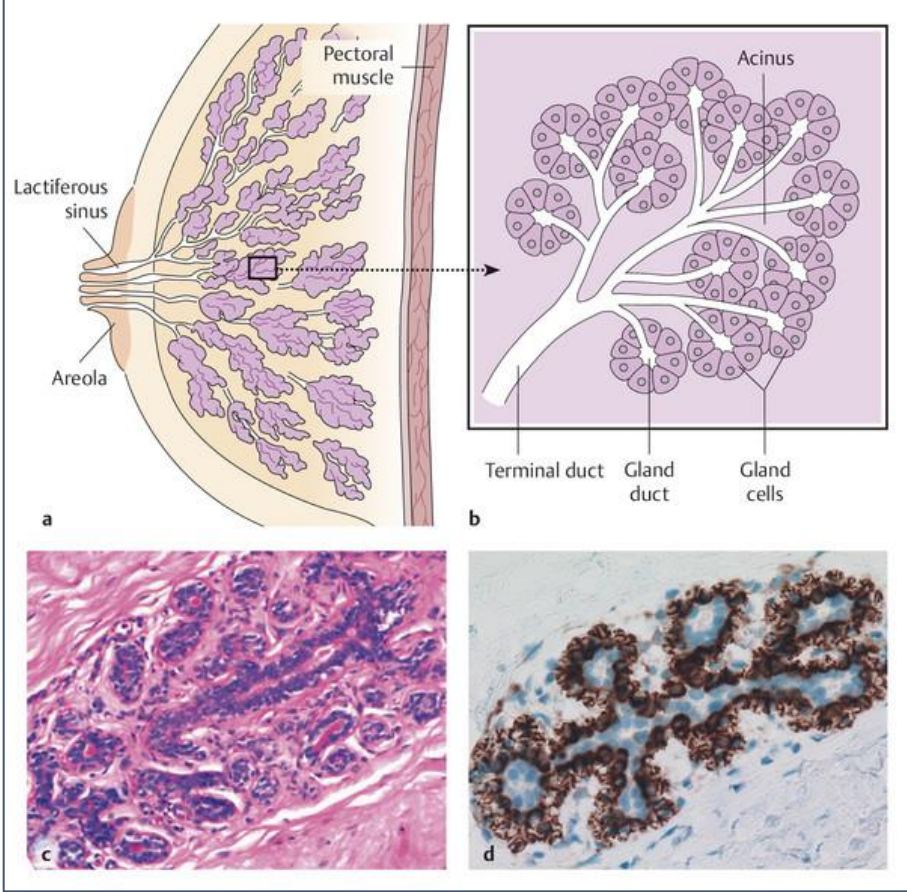
Section from right breast:



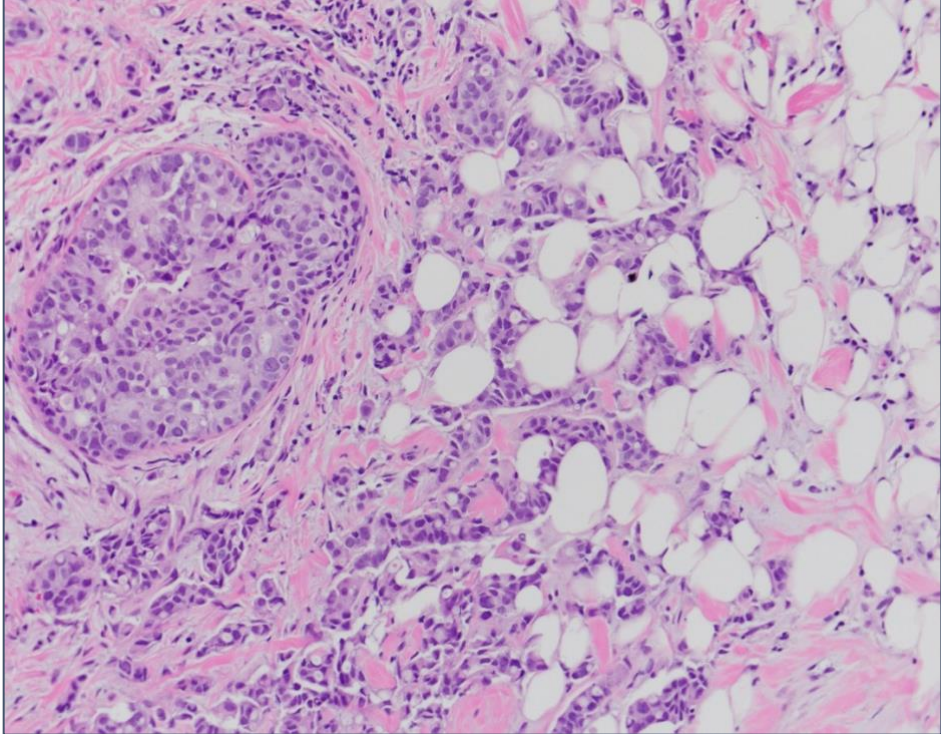
Higher magnification of right breast:



Schematic of normal breast anatomy:



Section from left breast:

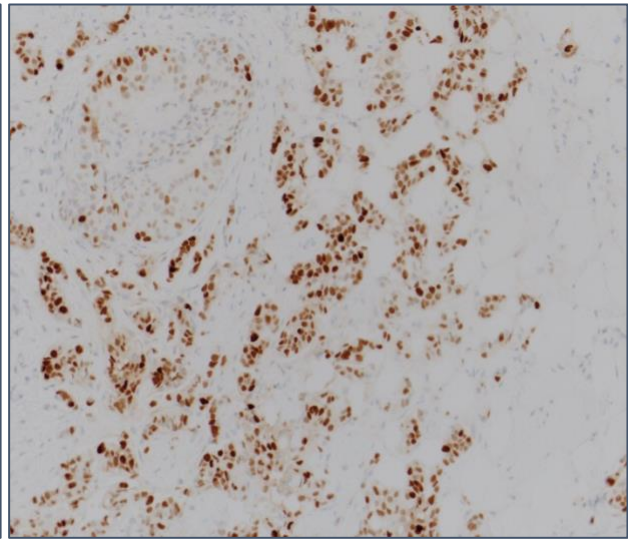
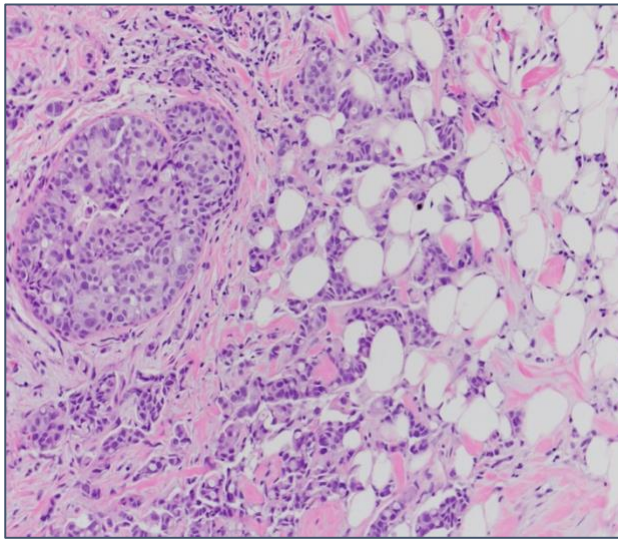


What do you see in the picture from the right breast?
What cell types do you see in the right breast?

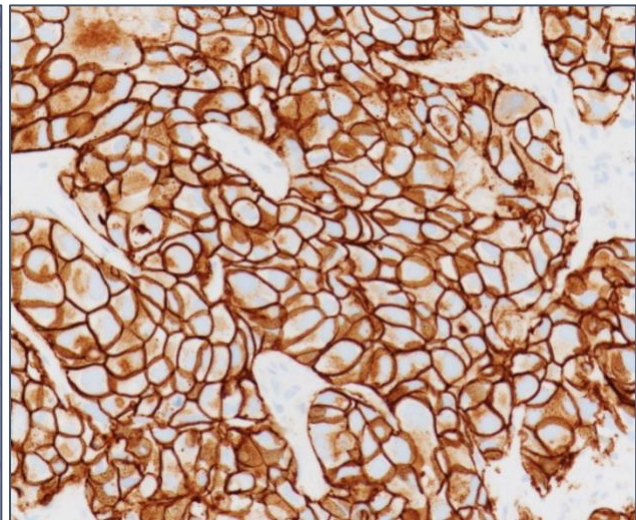
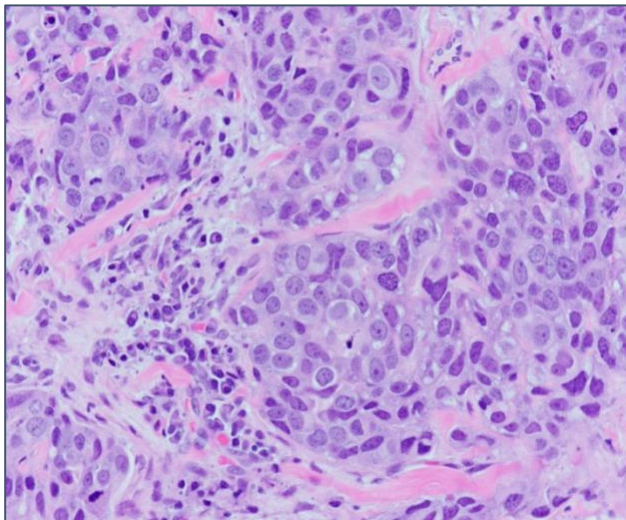
What do you see in the picture from the left breast?
Which picture shows normal breast tissue? Right or Left?
Which picture shows abnormal breast tissue? Right or Left?

The Pathologist (you) orders Immunohistochemistry staining for Estrogen receptor and HER2.
What is immunohistochemistry? Why were these stains ordered?

ER IHC:



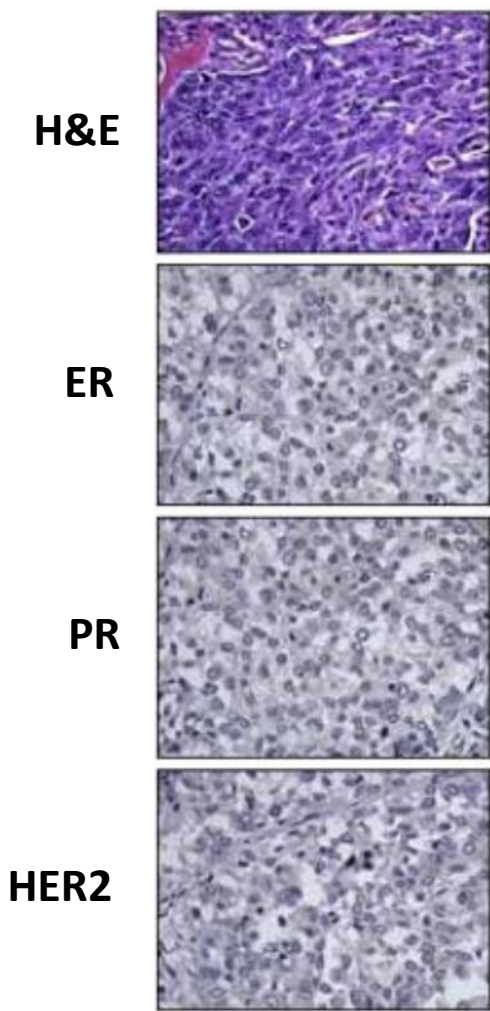
HER2 IHC:



What do you see from these IHC stains? How does this drive treatment of the patient?

The patient undergoes surgery to remove the mass in the left breast and neighboring lymph nodes. Pathology of the mass showed clean margins and some cells in the neighboring lymph nodes. The patient is placed on adjuvant Herceptin (trastuzumab) therapy. What is this therapy and why did they choose this instead of chemotherapy?

The patient goes into remission and returns to normal post-cancer screening for the next 4 years. In the fifth year of screening a mass is observed in the right lung of the patient. A fine needle biopsy is performed and the lung mass is stained with the normal stain and with ER, Progesterone receptor (PR) and HER2 given the history of breast cancer in the patient. The pathologist (you) sees this:



What is your conclusion from this staining?

Is this breast cancer tissue?

If this is breast cancer tissue do you think it was from the original primary tumor 5 years ago, if so why or why not?